

# Cryptococcal meningitis in Lubumbashi, DR Congo: Clinical Expressions and Diagnostic Procedures

Mbayo Lukasu<sup>1\*</sup>, Katabwa kabongo<sup>1</sup>, Kalumba kambote<sup>1</sup>, Mukeng A Kahut<sup>2</sup>, Kasamba Ilunga<sup>3</sup> and Wembonyama Okitosholo<sup>1</sup>

<sup>1</sup>Center of Excellence in HIV/Care, Lubumbashi, Democratic Republic of Congo, Africa

<sup>2</sup>Public Health School of Lubumbashi University, Lubumbashi, Democratic Republic of Congo, Africa

<sup>3</sup>Department of laboratory, university Clinic of Lubumbashi, Democratic Republic of Congo, Africa

\*Corresponding Author: Mbayo Lukasu, Center of Excellence in HIV/Care, Lubumbashi, Democratic Republic of Congo, Africa, E-mail: [xaviermulamba@gmail.com](mailto:xaviermulamba@gmail.com)

Received date: 18 Feb 2016; Accepted date: 17 Apr 2016; Published date: 22 Apr 2016.

Citation: Lukasu M, kabongo k, kambote K, Kahut MA, Ilunga K, et al. (2016) *Cryptococcal meningitis* in Lubumbashi, DR Congo: Clinical Expressions and Diagnostic Procedures. *J Emerg Dis Virol* 2(3): doi <http://dx.doi.org/10.16966/2473-1846.119>

Copyright: © 2016 Lukasu M, et al. This is an open-access article distributed under the terms of the Creative Commons Attribution License, which permits unrestricted use, distribution, and reproduction in any medium, provided the original author and source are credited.

## Background

The aim of this study was to describe the clinical, para clinical and evolutionary aspects of *Cryptococcal meningitis* in the HIV infection

**Methods:** This cross-sectional study collected clinical information from *Cryptococcal meningitis* patients with confirmed cerebral meningitis from 2011-2014 at Excellent Center. Fluconazole was the choice drug. The odds ratio and its 95 % confidence interval were expressed. The frequencies, the values of trends and dispersion were calculated. The Kappa coefficient was expressed to determine the relation among categorical variables matched the titer of Cryptococcal antigen.

**Results:** This study involved 52 patients. The meningeal syndrome was poorly represented 3 (5, 8%). Toxoplasmosis 14 (26.9%) was associated with signs of lateralization (OR=11, 95% CI=2.8-50, p=0.001). *Cryptococcal meningitis* was found in patients who were on antiretroviral in 38 (73.1%). A regression of clinical symptoms was observed in 26 (50%) who completed the treatment. The evolution was fatal in 26 (50%). Co-infections (OR=7, 5, 95% CI=2,002-28, p=0,003), and combination treatment (OR=16, 95% CI=3, 1-84, 2, p=0,000) were associated with the high lethality. The median TCD4+ lymphocytes count and IQR at diagnosis of *Cryptococcal meningitis* were 155 cell/mm<sup>3</sup> IQR (88-243). The Kappa coefficient from matching the titer of *Cryptococcal meningitis* was 1.

**Conclusion:** The title of Cryptococcal antigen should be interpreted in light of the evolution of clinical and duration required for treatment of cryptococcosis. Accessibility to the technical platform in this context seems urgent to improve the care of patients.

**Keywords:** HIV/AIDS; *Cryptococcal meningitis*

## Introduction

*Cryptococcal meningitis* (CM) is a most common opportunistic fungal disease in immune compromised [1]. This infection is caused by *Cryptococcus neoformans*, a yeast-fungus, encapsulated, cosmopolitan and living in several ecological niches [2] very frequent in Central Africa because of climatic and ecological conditions that favor its development and survival. Indeed, the yeast survives well in air at subtropical temperatures, which facilitates its. It is a therapeutic emergency. Its diagnosis requires a very expensive technical platform (Culture of cerebrospinal fluid, brain imaging), compromised by socio-economic insecurity, infrastructure, co-infection, no screening policy, late access to care and mass support. In addition, as cryptococcal antigen has a high specificity for the diagnosis of *Cryptococcal meningitis*. However, its significance for therapeutic monitoring is limited [3].

The central question that motivates this analysis is whether the clinical, laboratory and evolutionary aspects can contribute to the diagnosis of *Cryptococcal meningitis* considering disparities in socio-economic terms and technical facilities in different countries of the world with a look particularly on under-equipped countries. The aim of this study was to describe the clinical, paraclinical and evolutionary aspects of *Cryptococcal meningitis* during infection with human immune deficiency virus.

## Methods

### Study design and study participants

This is a cross sectional study conducted at Center of Excellence (C E) care of HIV / AIDS at the University of Lubumbashi in the Provincial Hospital Send us between 2011 -2014. The center provides care and exclusively the antiretroviral treatment services (ARVs) without exclusivity age and sex for free and the immunological and biological follow basic (lymphocytes TCD4+, hemoglobin, urea, creatinin and transaminases). The checkup of investigations of opportunistic infections (O.Is) and hospitalization were on the patients' charge. This center is typical of very Resource-limited Settings.

This study compiled 52 cases of *Cryptococcal meningitis* in patients living with HIV/AIDS who attended the Center of Excellence. Patients were included on essentially clinical criteria with systematic confirmation by cryptococcal antigen latex agglutination test readily available in Lubumbashi, Democratic Republic of Congo (DRC). Conducting brain imaging is not suited to our current practice due to the inaccessibility of this type of review. Lumbar puncture is not performed when the diagnosis is quickly confirmed by cryptococcal antigen test in blood. In addition, this diagnostic tool is of interest in both diagnosis and prognosis value [4]. However, only isolation *Cryptococcus neoformans* in cerebrospinal fluid (CSF) is used to assert the certainty of diagnosis [5,6].

For each patient, age, sex, have been clarified and the elements of interest below: the coexistence of other Opportunistic Infections, clinical manifestations, the lymphocytes TCD4+ and the change of the titer of cryptococcal antigen.

The determination of cryptococcal antigen and diagnosis of toxoplasmosis were conducted by the laboratory of mycology and parasitology of Lubumbashi's clinic university.

The treatment protocol consisted of Fluconazole as a loading dose (800 mg), consolidation dose (400 mg) and maintaining dose (200 mg). In this current practice, prophylaxis was routinely prescribed Co-trimoxazole. It does not happen for fluconazole.

### Statistical analysis

Chi square test and Fischer Exact test have been applied in case of small numbers ( $n < 5$ ) to measure the association among mixed treatment, co-infections and the outcome. Also to measure, the association between lateralisation's sign and toxoplasmosis. The significance level ( $p < 0.05$ ) and the Odds Ratio interpretable if its 95 % confidence interval excludes the value 1 . The frequencies, the values of trends and dispersion were calculated on selected cases. The test analysis was bilateral "two-tailed". The Kappa coefficient was expressed to determine the relation among categorical variables ordered according to three classes below: 1/4-1/8, 1/16-1/32 and 1/64-1/128. In addition, the kappa coefficient shows the interchange observed after treatment among different classes.

## Results

### Study population and baseline characteristics

Of the 2,100 persons living with HIV/AIDS who attended the Center of Excellence during the study period, 84 cases (4, 2%) of cryptococcal meningitis were compiled 52 cases which were selected on the basis of the diagnosis by cryptococcal antigen. In this group, female sex was predominant (27 Women /25 Men) or 52% .The mean age of  $41 \pm 13$  years. The demographics characteristics were illustrated in table 1.

### Clinical characteristics

Clinical signs were varied and illustrated in order of frequency importance in Figure 1. However, the lateralization's signs were associated with toxoplasmosis co-infection (OR=11, 95% CI=2.8-50,  $p = 0.001$ ).

Over 36.5% patients had, in addition to the cryptococcal meningitis other opportunistic infections illustrated by order of importance in the frequency (Figure 2).

### Biological characteristics

The titer of cryptococcal antigen test was positive in 52 cases before treatment and had varied after therapy for only 26 cases (50%) who survived had achieved control check. The Kappa coefficient was 1. The

Variables	Effect if (52)	Frequency (%)
<b>Sexes</b>		
Woman	27	52
Man	25	48
<b>Age (years)</b>		
$\geq 7$	1	1.92
7-45	32	61.54
>45-70	19	36.5

**Table 1:** The distribution of patients according to age and sex

median TCD4+ lymphocytes count and IQR at diagnosis of *Cryptococcal meningitis* were 155 cell/mm<sup>3</sup> IQR (88-243).

### Therapeutic characteristics

This study brought together the two categories of patients: those naive to ART; 14 cases (26.9%) and those on ART was 38 cases (73.1%).

The median and IQR variable length of hospital were 12 days IQR (8-16).

The median duration and IQR of the evolution of symptoms before diagnosis were 12 days IQR (9.5-15.3). The median duration and IQR of diagnosis were 2 days IQR (1-2). The laboratory made the deadline was 1 day.

All patients were put under fluconazole. The patients who had associated pathologies had received other treatments in addition to specific co-infections.

It's had noted a regression of signs clinics such as headache and fever in 90% of cases in the late first week of treatment against 9.6% who had impaired consciousness at the end of the second week of treatment.

The outcome was favorable in 26 (50%) cases, adverse in 26 (50%) cases. Co-infection (OR=7, 5, 95% CI=2,002-28,  $p=0,003$ ) and theirs combination treatments (OR=16, 95% CI=3, 1-84, 2,  $p=0,000$ ) and toxoplasmosis (OR=13 , 95% CI=19, 8-50, 2,  $p=0,000$ ) were associated with this strong lethality.

## Discussion

This cross sectional study was focused on the Para clinical features of cryptococcal meningitis to Lubumbashi, DR Congo. The diagnosis of cryptococcal meningitis is referred to etiological.

However, it goes through a phase through which the practitioner performs a history and physical examination at the end of which he asks syndromic diagnosis grouping anatomo-physiological entities responding to signs and symptoms presented by the patient. Then it will prescribe para clinical examinations guidance from which the practitioner will have to confirm his diagnosis.

In the same vein, the evidence of healing should be provided by a paraclinical control to the end of which one would observe an eradication of the pathogen in the sample or diminution of Markers of infection.

Fungal culture remains the gold standard for confirmation of the diagnosis of initial cryptococcal disease, confirmation of relapses or cases refractory to treatment, and adequate response to treatment [6].

Moreover, the output mode in this study was according to the duration of treatment with fluconazole and decreased as cryptococcal antigen as demonstrated mycological cure.

This could expose the failures and resistance by fluconazole.

Given the lack of access to culture, as cryptococcal antigen should be an important diagnostic tool in Lubumbashi, DR Congo.

Neither the culture nor the analysis of some elements of cerebrospinal fluid such as glucose, chlorid and protein level n has not been analyzed in this study. However, the latex agglutination test for the cryptococcal antigen allowed notifying, to refer and quickly initiate treatment of several cases of *Cryptococcal meningitis*.

Clinically, the most consistent signs were marked by headache and fever. In malaria endemic environment and other tropical infectious diseases, easily lend themselves to confusion and diagnostic deviations. This symptomatology was consistent to the study of Mbuagbaw et al. in Cameroon [7].

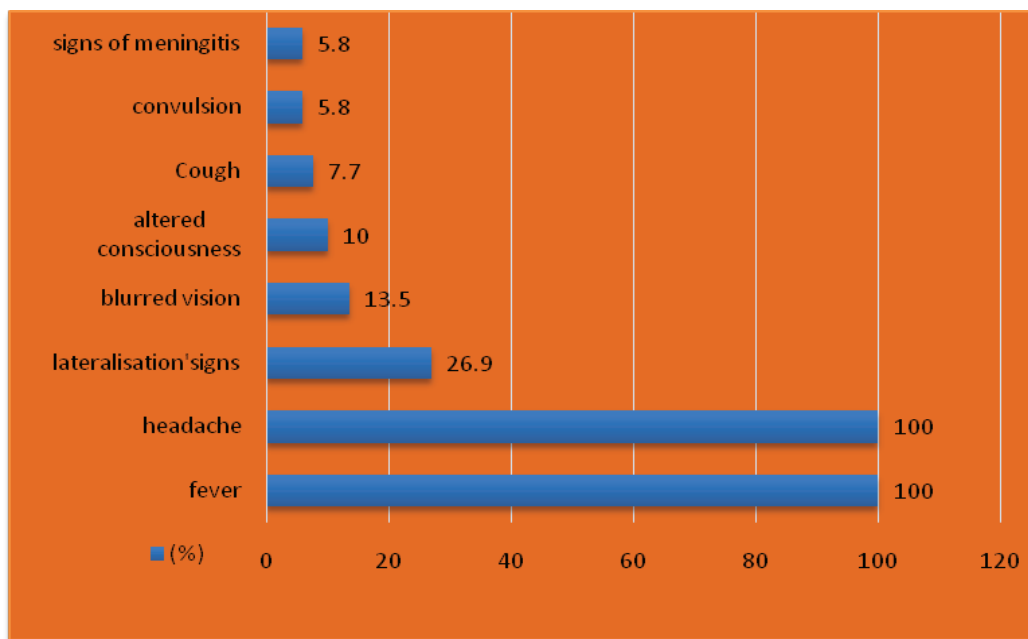


Figure 1: Clinical features of 52 cases of *Cryptococcal meningitis* who attended the Center of Excellence in care for HIV/AIDS 2011-2014

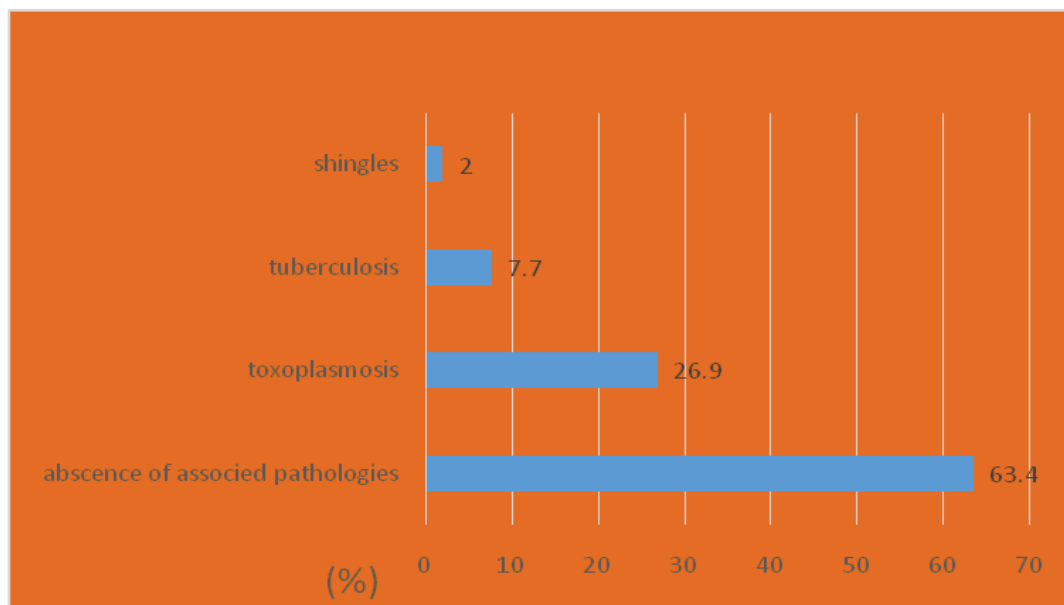


Figure 2: Pathologies related to 52 cases of *Cryptococcal meningitis* who attended the Center of Excellence in care for HIV/AIDS 2011-2014

The feverish focal neurological deficit was found in 14 (26.9%) of cases in our series and was associated with toxoplasmosis ( $p=0.001$ ). That is why in case of doubt the toxoplasma Elisa can slice and should be routinely performed in any patient with focused cryptococcal deficit.

The main opportunistic infections associated in this series were toxoplasmosis 14 (26.9%) and tuberculosis 4 (7.6%). These results are similar to those of Mbuagbaw et al. [7] as regards tuberculosis. However, no research specific to the diagnosis of other causative bacteria in sputum was realized.

This results in difficulty of establishing pathogenic associations accurately. Furthermore, this study suggests that these co-infections reflect

environmental exposure and make costly and long time the diagnosis process. This study brought together the two categories of patients: Those naive to ART such as the mode of entry into the care of Person living with HIV/AIDS ( $n=14$  (26.9%) cases and those on ART was 38 (73.1%) cases. These results suggest a supplementary survey on the incidence of *Cryptococcal meningitis* in patients on ARVs.

The outcome was adverse in 26 (50%) cases. This is sufficient proof that the emphasis should be on prophylaxis and routine screening for *Cryptococcal meningitis* in all seropositive patients and standardized therapeutic protocol according the World Organization of Health [6].

Fluconazole was the molecule of choice in Lubumbashi because of its cost, its easy handling and its prescription was free at the center of excellence. Thus, the availability and accessibility of this test is essential for rational use of fluconazole in daily practice.

### Conclusion

*Cryptococcal meningitis* remains relevant to Lubumbashi. Its diagnosis is available. However, the systematic screening in HIV patients with HIV and monitoring the efficacy remain pending.

In a context of economic uncertainty and challenge the technical platform, the titer of cryptococcal antigen test should be interpreted depending of the clinic evolution and duration required for treatment. Control of healing culture seems desirable. Thus, the proximity of the latter and the reduction of its cost should be increased its accessibility. Also, wider availability in the context of kit for the detection of soluble antigen would be crucial to improve the diagnosis by tracing patients suspected of *Cryptococcal meningitis*.

### Competing Interest

There are no competing interests to report.

### Acknowledgements and Funding

We thank kandja, Manda, Blessing, Kabika and all members of Center of Excellence in HIV/Care for their technical support. We received no funding for this study.

### Authors Contribution

(1) ML-Conception and design of the study, acquisition of data, involved in the drafting

(2) KK-Approving the final version to be published

(3) KK-Conception and design of the study

(4) MAK-Conception and design of the study, analysis and interpretation of data

(5) KI-Conception and design of the study, laboratory analysis, acquisition of laboratory data,

(6) WO-Accepting accountability for all aspects of the work.

### Conflict of Interest

All authors read and approved the final manuscript.

### References

1. Dismukes WE (1993) Management of cryptococcosis. *Clin Infect Dis* 2: S507-12.
2. Wang W, Carm AR (2001) A clinical manifestation of AIDS with *Cryptococcal meningitis* in Equatorial Guinea. *Trop Doct* 31: 221-222.
3. Lu H, Zhou Y, Yin Y, Pan X, Weng X (2005) Cryptococcal antigen test revisited: Significance for *Cryptococcal meningitis* therapy monitoring in tertiary Chinese hospital. *J Clin Microbiol* 43: 2989-2990.
4. Cunha BA (2001) Central nervous system infections in the compromised host: A diagnostic approach. *Infect Dis Clin North Am* 15: 567-590.
5. Katlama C, Lubetzki C (1998) Atteintes neurologiques. In: SIDA. Girard PM, Katlama C, Pialoux G, Doin (eds) 91-106.
6. WHO (2011) Rapid Advice: Diagnosis, Prevention and Management of cryptococcal disease in HIV-infected adults, adolescents and children.
7. Mbuagbaw JN, Biholong J, Nyamshi AK (2006) Cryptococcal meningitis and HIV in the internal medicine at the Yaoundé university teaching hospital, Cameroon. *Af J Neur Sci* 25: 98.