

## Single-Port Laparoscopy-Assisted Appendectomy in Children: A Method Described

**Maria Naredi\***, Magnus Anderberg, Pernilla Stenström, Einar Arnbjörnsson and Martin Salö

*Department of Pediatric Surgery, Skåne University Hospital, Lund, Sweden*

\*Corresponding author: Maria Naredi, Department of Pediatric Surgery, Skåne University Hospital, Lasarettsgatan 48, 221 85, Lund, Sweden, Tel: +4646175386; E-mail: [maria.naredi@hotmail.com](mailto:maria.naredi@hotmail.com)

**Received date:** 29 Mar 2016; **Accepted date:** 06 Apr 2016; **Published date:** 11 Apr 2016.

**Citation:** Naredi M, Anderberg M, Stenström P, Arnbjörnsson E, Salö M (2016) Single-Port Laparoscopy-Assisted Appendectomy in Children: A Method Described. *J Surg Open Access* 2(3): doi <http://dx.doi.org/10.16966/2470-0991.122>

**Copyright:** © 2016 Naredi M, et al. This is an open-access article distributed under the terms of the Creative Commons Attribution License, which permits unrestricted use, distribution, and reproduction in any medium, provided the original author and source are credited.

### Abstract

Single-incision laparoscopic appendectomy (SILA) has gained popularity in children, and several different techniques have been described, including intracorporeal and extracorporeal techniques and single-channel and multi-channel single-port techniques. However, there has been a concern that exteriorizing an infected appendix through the umbilical channel would increase the risk of postoperative wound infections. This report aims to describe a technique for single-port laparoscopy-assisted appendectomy (SPLAA) using an operative laparoscope and conventional laparoscopic instruments, as well as a VersaStep™ sheath to protect the wound edge while removing the appendix from the abdomen.

**Keywords:** Single-incision laparoscopic appendectomy; Single-port laparoscopy-assisted appendectomy; Appendectomy; Children

### Introduction

Acute appendicitis is a common cause of emergency surgery in children, but treatment choices continue to be a topic of discussion in medical literature [1,2]. In recent studies involving children, laparoscopic appendectomy (LA) has been shown to have several advantages, as compared with open appendectomy (OA). The presented advantages include a lower incidence of postoperative complications such as surgical wound infections and postoperative ileus, along with reduced postoperative pain; a more rapid recovery, including a quicker return to normal activities; a shorter hospital stay; and a better cosmetic result [2,3].

Since Kurt Semm [4] described a technique involving endoscopic appendectomy in 1983, several LA techniques have been discussed. Currently, the technology for performing LA utilizes one, two, three, or more trocars. In 1992, Pelosi was the first to describe a laparoscopic technique using a single umbilical incision only [5]. Since then, single-incision laparoscopic appendectomy (SILA) has gained popularity, and several different techniques including intracorporeal and extracorporeal techniques and single-channel and multi-channel single-port techniques have been described.

Intracorporeal laparoscopic techniques involve a single umbilical skin incision and multiple laparoscopic instruments inserted through several stab incisions in the fascia [6], specially designed multichannel single ports [7-9], or a multichannel single port created from a surgical glove [10]. Another intracorporeal technique uses an operative laparoscope and a transdermal suture to elevate the appendix and facilitate dissection and ligation of the appendix [11]. An operative laparoscope has also been widely used in an extracorporeal laparoscopy-assisted technique in which the appendix is grasped, exteriorized through the umbilical incision, and then dissected and ligated in a manner similar to that of a conventional open appendectomy [12-14].

There has been a concern that exteriorizing an infected appendix through the umbilical channel could increase the risk of postoperative wound infections. For this reason, we used a VersaStep™ sheath to protect the wound edge while exteriorizing the appendix. The present report aims to describe our single-port laparoscopy-assisted appendectomy (SPLAA) technique. We are not aware of any other reports in medical literature on the same technique.

### Operative Technique

The described method has been used in children with abdominal pain and with clinical findings justifying diagnostic laparoscopy. If acute appendicitis were suspected, the diagnosis was frequently supported or confirmed using ultrasonography or sometimes computer tomography [15,16]. Antibiotic prophylaxis is administered before the procedure [17].

Our single-port laparoscopy-assisted technique involves the use of a VersaStep™ Plus Access System with a 12-mm trocar provided by Covidien, Autosutur™. The trocar was inserted via an umbilical or subumbilical incision using an open-access technique. We use a transumbilical or subumbilical open access for the abdominal cavity but this technique could be used for any transabdominal Wall incision

Pneumoperitoneum was established with an intra-abdominal pressure of 8-12 mmHg, with a CO<sub>2</sub> flow rate of 1-2 l/min. The trocar was used for the insertion of a 0-grade operating laparoscopic optic 10-5 with a 5-mm working channel (Richard Wolf GmbH, Pforzthumer Strasse 33, 75438 Knittlingen, Germany). With the operative laparoscope in place, diagnostic laparoscopy was performed. The appendix was visualized, by tilting the child with the head down and partially rolled to the left side, if necessary.

If an inflamed appendix was found, the operating surgeon decided which modality would be best to remove the appendix from the abdominal cavity and thus selected children who were suitable for SPLAA. If the operating surgeon's decision to perform SPLAA is qualified, any later

conversion to two- or three-port LA or OA can be avoided. However, should conversion be necessary, this technique could easily permit the placement of additional trocars. The anatomical position of the appendix and adhesions fixating the appendix, as well as the surgeon's own experience with the procedure, are the main factors influencing the decision as to which surgical technique would be appropriate.

If the operating surgeon decided that SPLAA was possible, a conventional laparoscopic instrument, e.g., Maryland or Babcock, was inserted through the working channel of the operative laparoscope, and the tip of the appendix was grasped (Figure 1). The appendix was moved to the tip of the optic. The optic and appendiceal tip were then drawn into the 12-mm VersaStep™ trocar. The optic, appendiceal tip, and 12-mm VersaStep™ trocar were drawn into the VersaStep™ sheath (Figure 2), which enfolded the appendix and held it in place. This sheath replaces an endoscopic bag. Withdrawing the VersaStep™ sheath exteriorized the base of the appendix.

When the appendix was in the extracorporeal position, the grasper was substituted with a conventional Babcock. Electric cautery was used to divide and seal the vessels in the mesoappendix along the appendix. The appendix was ligated at its base with an absorbable suture and then removed. After removing the appendix, the abdominal cavity was

inspected, ensuring hemostasis. Finally, the abdominal gas was emptied; the trocar wound was sutured; and a local anesthetic was injected around the wound.

We usually use a transumbilical or subumbilical open access for the abdominal cavity. This technique could be used for any transabdominal wall incision.

## Discussion

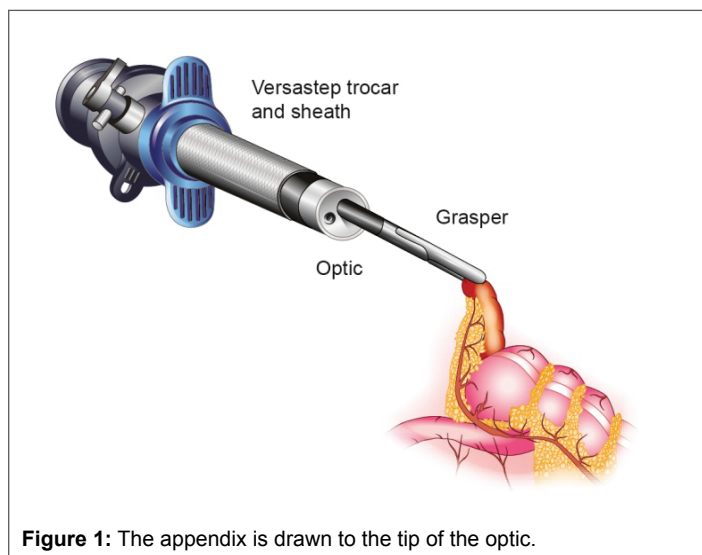
In this report, we described an SPLAA technique. The technique differs from those previously described because of the use of a VersaStep™ sheath that protects the umbilical tissue from contact with the inflamed appendix, theoretically decreasing the risk of postoperative wound infections. A similar technique using a VersaStep™ sheath as a wound protector has been previously described in a two-trocar laparoscopic appendectomy that demonstrated no increased wound infection rate if the appendix was exteriorized through a VersaStep™ sheath [18].

LA has been shown to have several advantages, as compared with OA [2,3]. Theoretically, the benefits should be even greater with only one umbilical incision, as compared with two, three, or more incisions through the abdominal wall. A recent systematic review and meta-analysis comparing SILA (using intracorporeal and extracorporeal techniques and single-channel and multichannel single-port techniques) and conventional LA in children concluded that SILA was a safe procedure in children but did not have any superiority to conventional LA. Patients undergoing SILA demonstrated a significantly higher incidence of wound infections, as compared with those undergoing conventional LA [19].

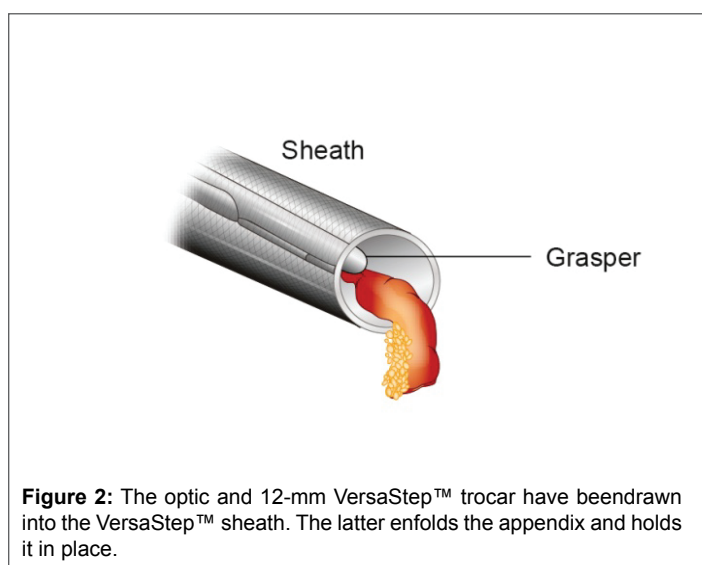
If the inflamed appendix is exteriorized through the umbilical channel using the SILA technique, one of the most discussed disadvantages is the potential for an increased risk of postoperative wound infections. Studies describing SPLAA using techniques similar to ours, but without any wound edge protection, demonstrated an incidence of wound infections ranging from 0.4% to 7.5% [13,14,20,21]. In a study comparing an SPLAA technique without wound protection with conventional LA, the incidence of wound infections was 13.7% in the SPLAA group and 4.6% in the LA group, but the difference was not significant [22]. In reports regarding the use of a wound retractor as a wound protection method while exteriorizing the appendix through an umbilical or subumbilical incision, no postoperative wound infections were reported [8,23,24]. With our technique, the VersaStep™ sheath enfolds an inflamed appendix that prevents contact with the umbilical tissue. However, there is a lack of randomized or comparative studies that clearly concluded a decreased incidence of wound infections with wound protection.

Other surgical benefits of the SPLAA technique include: an appendectomy is performed without intra-abdominal cautery, excluding the risk of diathermic injury to the bowels, and the appendix is ligated with an absorbable suture, leaving no metal clips in a growing child's body. The time from incision to closure could probably be reduced with the SPLAA technique, as compared with a conventional three-port LA, because less time is needed for port insertion and wound closure and because extracorporeal dissection and ligation is less time-consuming than intracorporeal dissection. One disadvantage of the technique is that the method might be difficult or even impossible to perform if the appendix is in a retrocecal position or is surrounded by adhesions. The described method is better suited for children rather than adults because children often have a mobile cecum, short distance from the umbilicus to the appendix, and thin abdominal wall. In older children, the method might be more difficult to perform.

Our SPLAA method could be beneficial from an economic perspective because conventional laparoscopic instruments can be used and fewer instruments are necessitated and the operating time can probably be



**Figure 1:** The appendix is drawn to the tip of the optic.



**Figure 2:** The optic and 12-mm VersaStep™ trocar have been drawn into the VersaStep™ sheath. The latter enfolds the appendix and holds it in place.

reduced, as compared with conventional LA. Future research with randomized, prospective studies would have to be conducted to determine which operative technique is best for acute appendicitis in children. Randomization has to be performed after diagnostic laparoscopy to enable the fair selection of patients for operative treatment options.

### Conclusion

This report aimed to describe an operative technique for single-port laparoscopy-assisted appendectomy in children. Therefore, no conclusions could be drawn regarding wound infections, duration of surgery, costs, or which operating technique that should be used.

### Acknowledgements

Elsevier WebShop-Illustration Service for drawing the figures.

### References

- Svensson JF, Patkova B, Almström M, Naji H, Hall NJ, et al. (2015) Nonoperative treatment with antibiotics versus surgery for acute nonperforated appendicitis in children: a pilot randomized controlled trial. *Ann Surg* 261: 67-71.
- Esposito C, Calvo AI, Castagnetti M, Alicchio F, Suarez C, et al. (2012) Open versus laparoscopic appendectomy in the pediatric population: a literature review and analysis of complications. *J Laparoendosc Adv Surg Tech A* 22: 834-839.
- Aziz O, Athanasiou T, Tekkis PP, Purkayastha S, Haddow J, et al. (2006) Laparoscopic versus open appendectomy in children: a meta-analysis. *Ann Surg* 243:17-27.
- Semm K (1983) Endoscopic appendectomy. *Endoscopy* 15: 59-64.
- Pelosi MA, Pelosi MA 3<sup>rd</sup> (1992) Laparoscopic appendectomy using a single umbilical puncture (minilaparoscopy). *J Reprod Med* 37: 588-594.
- Ostlie DJ (2011) Single-site umbilical laparoscopic appendectomy. *Semin Pediatr Surg* 20: 196-200.
- Chandler NM, Danielson PD (2010) Single-incision laparoscopic appendectomy vs multiport laparoscopic appendectomy in children: a retrospective comparison. *J Pediatr Surg* 45: 2186-2190.
- Deie K, Uchida H, Kawashima H, Tanaka Y, Masuko T, et al. (2013) Single-incision laparoscopic-assisted appendectomy in children: exteriorization of the appendix is a key component of a simple and cost-effective surgical technique. *Pediatr Surg Int* 29: 1187-1191.
- Lee SE, Choi YS, Kim BG, Cha SJ, Park JM, et al. (2014) Single port laparoscopic appendectomy in children using glove port and conventional rigid instruments. *Ann Surg Treat Res* 86: 35-38.
- Kim HJ, Lee JI, Lee YS, Lee IK, Park JH, et al. (2010) Single-port transumbilical laparoscopic appendectomy: 43 consecutive cases. *Surg Endosc* 24: 2765-2769.
- Lee SY, Lee HM, Hsieh CS, Chuang JH (2011) Transumbilical laparoscopic appendectomy for acute appendicitis: a reliable one-port procedure. *Surg Endosc* 25: 1115-1120.
- Esposito C (1998) One-trocar appendectomy in pediatric surgery. *Surg Endosc* 12: 177-178.
- Sesia SB, Haecker FM, Kubiak R, Mayr J (2010) Laparoscopy-assisted single-port appendectomy in children: is the postoperative infectious complication rate different? *J Laparoendosc Adv Surg Tech A* 20: 867-871.
- Codrich D, Scarpa MG, Lembo MA, Pederiva F, Olenik D, et al. (2013) Transumbilical laparo-assisted appendectomy: a safe operation for the whole spectrum of appendicitis in children-a single-centre experience. *Minim Invasive Surg* 2013: 216416.
- Salö M, Friman G, Stenström P, Ohlsson B, Arnbjörnsson E (2014) Appendicitis in children: evaluation of the pediatric appendicitis score in younger and older children. *Surg Res Pract* 2014: 438076.
- Arnbjörnsson E, Mikaelsson C (1984) Importance of preoperative antibiotic prophylaxis for patients undergoing acute appendectomy. *Lancet* 2: 1279.
- Salö M, Järbur E, Hambreaus M, Ohlsson B, Stenström P et al. (2016) Two-trocar laparoscopic appendectomy in children. Unpublished.
- Salö M, Ohlsson B, Arnbjörnsson E, Stenström P (2015) Appendicitis in children from a gender perspective. *Pediatr Surg Int* 31: 845-853.
- Zhang Z, Wang Y, Liu R, Zhao L, Liu H, et al. (2015) Systematic review and meta-analysis of single-incision versus conventional laparoscopic appendectomy in children. *J Pediatr Surg* 50: 1600-1609.
- Koontz CS, Smith LA, Burkholder HC, Higdon K, Aderhold R, et al. (2006) Video-assisted transumbilical appendectomy in children. *J Pediatr Surg* 41: 710-712.
- Ohno Y, Morimura T, Hayashi S (2012) Transumbilical laparoscopically assisted appendectomy in children: the results of a single-port, single-channel procedure. *Surg Endosc* 26: 523-527.
- Visnjic S (2008) Transumbilical laparoscopically assisted appendectomy in children: high-tech low-budget surgery. *Surg Endosc* 22: 1667-1671.
- Fukuzawa T, Mizuno M, Nakajima J, Nishizuka S, Kimura Y, et al. (2011) Laparoscopy-assisted appendectomy through an umbilical port in children. *Asian J Endosc Surg* 4: 11-15.
- Kang DB, Lee SH, Lee SY, Oh JT, Park DE, et al. (2012) Application of single incision laparoscopic surgery for appendectomy in children. *J Korean Surg Soc* 82: 110-115.