

The Etiology and Management of the Massive Retrosternal Goiters “Mediastinal”; A Case Report and Review of the Literature

Hajjar WM^{1*}, Aldahri S², Alotaibi AS³, Saeed AI³, Alturki FY³, Alsaleh WH³ and Hajjar AW⁴

¹Department of Thoracic Surgery, King Khalid University Hospital, College of Medicine, King Saud University, Riyadh, Saudi Arabia

²Department of Head and Neck Surgical Oncology, College of Medicine, King Saud University, Riyadh, Saudi Arabia

³College of Medicine, King Saud University, Riyadh, Saudi Arabia

⁴College of Medicine, Alfaisal University, Riyadh, Saudi Arabia

*Corresponding author: Hajjar WM, Associate Professor, Department of Thoracic Surgery, King Khalid University Hospital, College of Medicine, King Saud University, Riyadh, Saudi Arabia; Tel: 00966-11-4671575; E-mail: washajjar@yahoo.com

Received date: 06 Nov 2017; Accepted date: 11 Dec 2017; Published date: 15 Dec 2017.

Citation: Hajjar WM, Aldahri S, Alotaibi AS, Saeed AI, Alturki FY, et al. (2017) The Etiology and Management of The Massive Retrosternal Goiters “Mediastinal”; A Case Report and Review of the Literature. J Infect Pulm Dis 4(1): doi <http://dx.doi.org/10.16966/2470-3176.130>

Copyright: © 2017 Hajjar WM, et al. This is an open-access article distributed under the terms of the Creative Commons Attribution License, which permits unrestricted use, distribution, and reproduction in any medium, provided the original author and source are credited.

Abstract

Retrosternal goiter (RSG) is an enlargement of the thyroid gland that extends downward into the thoracic inlet secondary to benign conditions of the thyroid, and to a lesser extent, it can reflect malignancies. We report here a case of 57-year old female who was known to have a multinodular goiter with Hashimoto's thyroiditis. Radiological investigations showed a large thyroid goiter with huge retrosternal extension. She was operated upon by a Kocher transverse collar neck incision which was used for total thyroidectomy of both components, the neck, and the retrosternal parts, histopathology report showed papillary thyroid microcarcinoma with a background of Hashimoto's thyroiditis. Post-operative recovery was uneventful. The etiology and the possible causes of the thyroid retrosternal extension will be discussed in this report.

Keywords: Retrosternal goiter; Hashimoto's thyroiditis; Papillary microcarcinoma; Multinodular goiter

Introduction

'Goitre' is a term derived from the Latin 'tumidum gutter' swollen throat. It is defined as a thyroid gland that is double in size, or weights more than 40 g [1]. Retrosternal, sub-sternal, intra-thoracic, or mediastinal are terms to describe a goiter beyond the thoracic inlet [1]. However, RSG occurs when the thyroid grows downwards from the neck into the chest cavity. These goiters remain in the chest, usually entirely asymptomatic and undetected, until it's discovered as an incidental finding. Wide mediastinum, the negativity of thoracic pressure and gravity all can contribute to the goiter being retrosternal [2]. Nowadays, different surgical options have been used for the surgical resection of this type of goiters, which is related to the size of the gland and the location, such as collar neck incision or/and sternotomy, Clamshell incision, or even thoracotomy [3].

Case Report

A 57 year-old female, presented with painless neck swelling of 20 years duration as she was known to have a multinodular goiter with Hashimoto's thyroiditis. Recently, for the last six months, she started to experience upper chest discomfort without dyspnea, dysphagia or symptoms of hyperthyroidism or hypothyroidism. She has a positive family history of benign simple goiter. Neck examination revealed a large neck mass extending bilaterally, and behind the manubrium, and unable to feel the lower border of the gland, neither non-tender nor pulsatile on palpation with a rubbery consistency.

Ultrasound examination showed enlargement of the whole thyroid gland, the right lobe measures 5 x 4 cm while the left lobe 7 x 5 cm. The

finding suggested multinodular goiter with some cystic changes and calcifications. Chest X-ray showed a large superior mediastinal mass, soft tissue density lesion, mainly at right side compressing the trachea to the left side (Figure 1).

CT scan chest with contrast showed massive enlargement of the thyroid gland with multiple heterogeneous hypodense nodules with a retrosternal extension reaching the anterior mediastinum and subsequent vascular venous compression (Figure 2 a-e).

Initial histopathology of this thyroid obtained by fine needle aspiration revealed benign follicular cells, cyst macrophages, and colloid, with no malignant cells.

The patient underwent total thyroidectomy through transverse collar neck incision under general anesthesia. However, the whole thyroid of both components was excised completely from this incision without median sternotomy (Figure 3). The patient was extubated immediately in the operating room. The post-operative recovery was uneventful, she was discharged home after few days without any complications on simple analgesia. Follow up in the outpatient clinic OPC continued for 12 months without any related complaints and her chest X-ray remained normal (Figure 4).

The final histopathology report of the total thyroid specimen revealed a large thyroid gland weighing 550 gm, the right lobe measures 15 x 9 x 5 cm, and the left lobe measures 11 x 8 x 5 cm, in addition, it showed papillary microcarcinoma of the thyroid with a background of Hashimoto's thyroiditis.

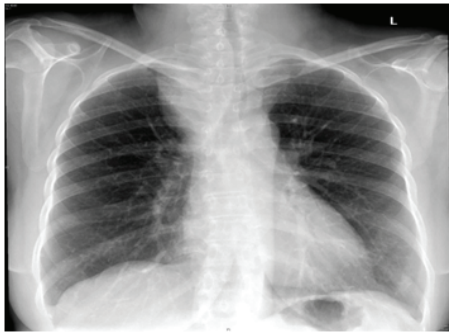


Figure 1: Chest X-ray showing large superior mediastinal mass, soft tissue density lesion, mainly at right side compressing the trachea to the left side.

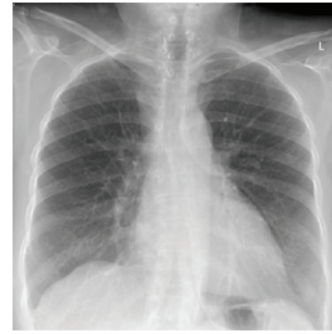

Figure 4: Chest X-ray post-operative showing regression of the superior mediastinum after the surgical resection of the large RSG.

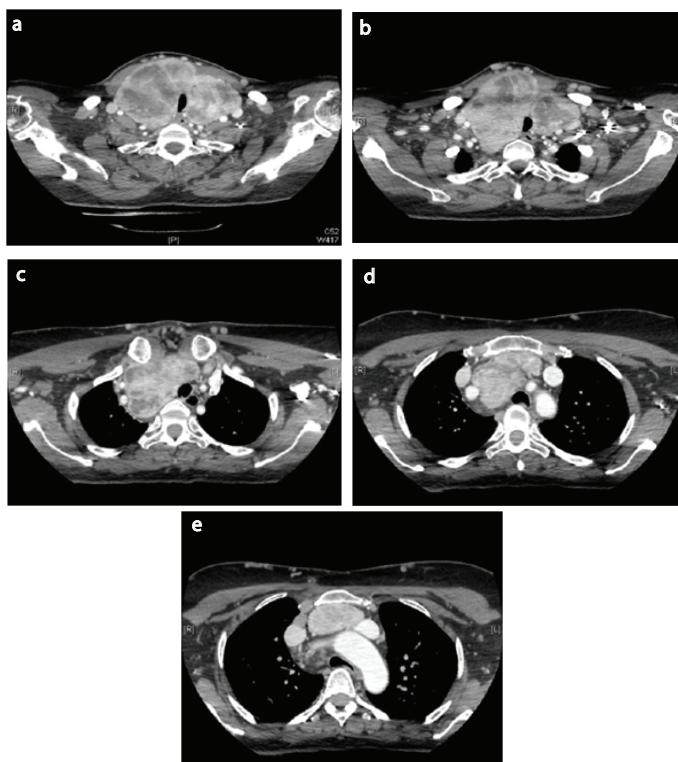


Figure 2: CT scan chest with I.V. contrast "different levels" showing massive enlargement of the thyroid gland with multiple heterogeneous hypodense nodules with retrosternal extension reaching the anterior mediastinum and subsequent vascular venous compression.

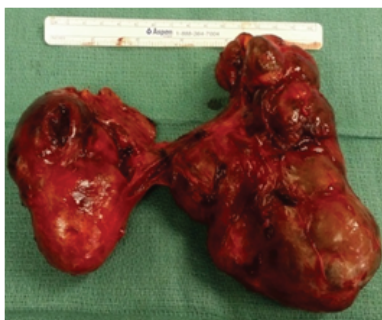

Figure 3: Specimen of the whole thyroid gland after resection with both components the neck and the mediastinal parts.

Discussion

Hashimoto's thyroiditis is a chronic autoimmune disease in which the thyroid gland is gradually destroyed. Affected patients with this disease usually present with a goiter and hypothyroidism picture. The disease is seven times more likely to occur in women than men [4]. Patients afflicted with Hashimoto's thyroiditis have a higher risk of thyroid malignancies such as papillary thyroid carcinoma and thyroid lymphoma [4], among patients who undergo thyroidectomy; the incidence of RSG is about 3%–20% [5]. There are some factors that help to understand the reasons and the etiology of the extension of the goiters downward the thoracic cavity. The mediastinum space size is not fixed, yet it has the ability (potential space) to lodge abnormally growing lesions. As a result, the more potential space of an individual's mediastinum, the higher the likelihood of RSG. In addition, the intra-pleural negative pressure and gravity could play a role in this mechanism [2].

The majority of RSG are benign pathology and can exist from any causes of the goiter conserved in the neck such as iodine deficiency, ingestion of goitrogenic food and familial forms. Although 40% of RSG can be asymptomatic, many may complain of pressure symptoms such as dyspnea, stridor, orthopnea, dysphagia and hoarseness due to compression of the surrounding structures including the airway (the most alarming), esophagus and neurovascular structures, or presents with signs and symptoms of thyrotoxicosis [2]. Also, a positive Pemberton sign could be seen, pointing towards superior vena cava obstruction. In our previous report in 2012 [3], and in other reports such as El Hammoumi et al. [6] and others showed that the treatment of choice of RSG is the early recognition and surgical removal by Kocher transverse collar neck incision with very low surgical complications [7,8]. On the other hand; in rare circumstances such as carcinoma of invasive nature, the presence of ectopic thyroid gland, or previous cervical thyroidectomy; a sternotomy could be mandatory [9].

Also, very rarely an unusual method for RSG excision could be used by a Clamshell incision under the 5th intercostal spaces extending 7 cm right and left from the midline for special cases with giant goiters [10]. Our case report, presented with a very large RSG extension and weighing around 550 gm., has been delivered completely through the neck incision with preservation of the main neck structures like thoracic duct, recurrent laryngeal nerves and major vessels, with full considerations of a few intraoperative measurements or maneuvers like using reverse Trendelenburg position to minimize the neck vessels congestion and the bleeding, and preparing both neck and sternum in case median sternotomy exposure was needed.

Conclusion

Our case was known to have a multinodular goiter with Hashimoto's thyroiditis, recently, for the last six months, she was presented with

a pressure symptom as a massive RSG due to a papillary thyroid microcarcinoma that was surgically resected as a total thyroidectomy through a transverse neck incision. The patient remained very well postoperative on a regular followup in the OPC.

However, the etiology and the possible causes of growing these types of RSG in the mediastinum prior to being presented with pressure symptoms have been discussed thoroughly in this report, in addition the treating physician should be alert for the early diagnosis and management by surgical resection before any pressure symptoms to minimize the possible complications and the morbidity.

Ethics or IRB

As we are reporting only a case report and not a study or a clinical trial, ethical permission was not applied and ethical permission from the local Ethical Committee or Institutional Review Board was not obtained for this case report, but a valid written consent was obtained from the patient himself.

Conflict of Interest

The authors declare no conflict of interest in preparing this article.

Acknowledgement

We are grateful to the Deanship of Scientific Research, King Saud University, Riyadh, Saudi Arabia, for supporting the work through the research group (RGP-VPP-181)

References

- Huins CT, Georgalas C, Mehrzad H, Tolley NS (2008) A new classification system for retrosternal goitre based on a systematic review of its complications and management. *Int J Surg* 6: 71-76.
- Shen WT, Kebebew E, Duh QY, Clark OH (2004) Predictors of airway complications after thyroidectomy for substernal goiter. *Arch Surg* 139: 656-659.
- Khairy GA, Al-Saif AA, Alnassar SA, Hajjar WM (2012) Surgical management of retrosternal goiter: Local experience at a university hospital. *Ann Thorac Med* 7: 57-60.
- Replinger D, Bargren A, Zhang YW, Adler JT, Haymart M, et al. (2008) Is Hashimoto's thyroiditis a risk factor for papillary thyroid cancer? *J Surg Res* 150: 49-52.
- Moran JC, Singer JA, Sardi A (1998) Retrosternal goiter: A six-year Institutional Review. *Am Surg* 64: 889-893.
- El Hammoumi M, El Oueriachi F, Arsalane A, Kabiri EH, Clave P (2014) Surgical Management of Retrosternal Goitre: Experience of a Moroccan Center. *Acta Otorrinolaringol Esp* 65: 177-182.
- Conzo G, Avenia N, Ansaldo GL, Calò P, De Palma M, et al. (2017) Surgical treatment of thyroid follicular neoplasms: results of a retrospective analysis of a large clinical series. *Endocrine* 55: 530-538.
- Gambardella C, Tartaglia E, Nunziata A, Izzo G, Siciliano G, et al. (2016) Clinical significance of prophylactic central compartment neck dissection in the treatment of clinically node-negative papillary thyroid cancer patients. *World J Surg Oncol* 14: 247.
- De Perrot M, Fadel E, Mercier O, Farhamand P, Fabre D, et al. (2007) Surgical management of mediastinal goiter; when is sternotomy required? *Thorac Cardiovasc Surg* 55: 39-43.
- Komninos G, Galata G, Schulte KM (2014) Giant recurrent intrathoracic goitre treated by clamshell thoracotomy and reverse sternotomy. *BMJ Case Rep*. pii: bcr2013202790.