

Pediatrics and Neonatal Nursing: Open Access

Case Report

Volume: 1.2

Open Access

Aqueous 0.5% Chlorhexidine Induced Chemical Spillage Burns: Use of a Novel Flexible Silicone Dressing Gel

Archana Priyadarshi^{1*} and James Marceau²*Neonatal Intensive Care Unit, Westmead Hospital, The University of Sydney, Australia**Neonatal Intensive Care Unit, Westmead Hospital, Australian College of Neonatal Nursing, Australia*

Corresponding author: Dr Archana Priyadarshi, Neonatal Intensive Care Unit, Westmead Hospital, P.O Box 533, Wentworthville, NSW 2145, Australia, Tel: 0061 11 298457375; Fax: 0061-2-98457490; **E-mail:** archanapriyadarshi@yahoo.co.in

Received date: 11 Sep 2015; **Accepted date:** 13 Nov 2015; **Published date:** 17 Nov 2015

Citation: Priyadarshi A, Marceau J (2015) Aqueous 0.5% Chlorhexidine Induced Chemical Spillage Burns: Use of a Novel Flexible Silicone Dressing Gel. *Pediatr Neonatal Nurs Open Access* 1(2): doi <http://dx.doi.org/10.16966/2470-0983.107>

Copyright: © 2015 Priyadarshi A, et al. This is an open-access article distributed under the terms of the Creative Commons Attribution License, which permits unrestricted use, distribution, and reproduction in any medium, provided the original author and source are credited.

Summary

A 24 week gestation male triplet infant received partial thickness burns along the left and right sides of his chest and abdomen as a result of prolonged skin contact with residual antiseptic solution whilst nursed under radiant heat. There was a delay in the recognition of these injuries. We attempted to treat these chemical burn injuries with the use of a novel silicone dressing gel and achieved good clinical outcome with early efficacious healing and no remnant scar tissue.

Background

This case demonstrates the complication of a routinely used antiseptic solution for cleaning the umbilical cord area during placement of umbilical catheters in extremely premature infants. To our knowledge, there have not been any reported cases of chemical-spillage burns with this solution. The epidermal layer of the skin in a premature infant is only 1-2 cells thick and offers little protection as a barrier.

Our case, an extremely preterm infant suffered chemical burns due to prolonged exposure of the skin with the pooled antiseptic solution used for cleaning the umbilical cord area. We attempted treating these chemical burns with the use of a novel silicone dressing gel that offered efficacious healing of the burnt areas in addition to preventing transepidermal water losses. The effectiveness of the silicone dressing gel was seen in a dramatic transformation of the original skin burn injuries to complete healing within four days after application.

Case Presentation

Chlorhexidine antiseptic solution (Chlorhexidine Acetate 0.5%, Baxter, Australia) was used to prepare the skin of a 24 week gestation, 600 g triplet male infant prior to insertion of the umbilical venous (UVC) and umbilical arterial catheter (UAC), at about 30 minutes of life post initial stabilisation after birth. This infant immediately after birth was wrapped into a polyethylene drape to prevent transepidermal water and heat loss. To facilitate adequate access for the procedure, overhead radiant heat was used from the open care incubator during the procedure and for one hour afterwards to maintain optimal thermal management of the infant, as outlined in the unit's thermoregulation policy. A mandated policy of our hospital directs that a skin risk assessment using a validated skin risk assessment tool be completed within the first eight hours after any admission to the neonatal intensive care unit. However, in this infant, 18 hours passed until it was noticed that 2 areas of skin on the infant's left and right flanks had sustained significant burns (Figure 1). Early detection, with immediate irrigation of the burnt areas of the skin with normal saline could have reduced the extent and progression of the injury.

We believe the burns were caused by a combination of prolonged direct chemical exposure of the infant's skin from the pooling of the residual

chlorhexidine solution on the polyethylene drape, forming a gutter. In addition it is likely the radiant heat from the overhead open care warmer contributed to warming up of this pooled aqueous chlorhexidine solution resulting in a combination of thermal and chemical burns.

On consultation with a paediatric burn specialist, partial-thickness burns estimated to cover 3-4% of the total body surface area of the infant were confirmed. The recommended treatment was to use a dressing that would encourage moist wound healing [1] such as Mepilex Lite (Mölnlycke Health Care, Sweden). Mepilex Lite is a foam dressing that has a soft silicone adhesive layer that adheres to the skin. The infant was in 80% incubator humidity at the time of the burns, making it difficult to cover the burnt areas of skin with the silicone-impregnated dressing alone. To overcome this, a decision was made to use a novel flexible silicone dressing gel (Strata-XRT, Stratpharma, Switzerland) registered as class IIa medical device, prior to the application of the Mepilex Lite dressings. Pain relief was achieved by the use of intravenous infusion of Morphine until 4 days post burns.

The gel on application to the skin forms a flexible protective silicone covering, which on drying is gas permeable, waterproof and enables wound healing by re-epithelialisation [2]. The fine layer of the silicone gel protects the damaged epidermal layer of the skin from friction secondary to factors such as linen or patient handling during cares. The drying of

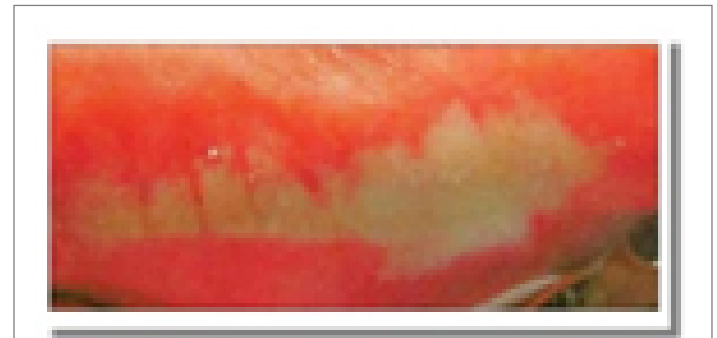

Figure 1: Burns detected on the skin along the chest and abdomen at 18 hours of life

the gel promotes moist wound healing by creating a micro-environment conducive to the proliferation of phagocytes, macrophages [3] and has also been reported to be involved in the dermo-epidermal signalling associated with fibroblast production [4] by increasing the basic fibroblast growth factors (bFGF), vital for wound healing [5].

In the case of our patient, we applied the silicone gel (Strata-XRT) daily to the damaged areas of the skin and then covered them with Mepilex Lite dressing for 14 days. Four days after commencing this treatment, healing was noticed (Figure 2) followed by efficacious healing of the burns by 4 weeks of age with no hypertrophic scarring, though areas of hypopigmentation were noted at the site of the injury (Figure 3).

Follow-Up

Follow up at one year of age revealed the persistence of those hypopigmented patches with no visible scars.

Discussion

There have been similar cases reported [6-9] involving chemical spillage burns in preterm infants associated with the use of 2% chlorhexidine solution in 70% isopropyl alcohol. Treatment of these injuries has ranged from use of plain dressings only to the use of silver impregnated dressings. In our case, we attempted a novel treatment with the use of silicone impregnated dressings in combination with daily application of the Silicone dressing gel in the treatment of chemical burns.

We believe that the application of the silicone gel sheeting in addition to the Mepilex Lite dressing facilitated healing by re-epithelialisation, acted as a barrier preventing transepidermal water loss and protected the injured fragile skin from friction injuries. We also believe that this injury could have been prevented if the polyethylene drape was removed prior to skin cleaning and absorbent linen was placed underneath the infant to soak the residual antiseptic solution.

We found favourable treatment results with the use of the silicone dressing gel demonstrated as early effective healing with no residual hypertrophic scars. More trials on the use of this product are required to confirm its use as an efficacious treatment option for chemical burn injury in neonates. We would also like to caution about the residual areas of hypopigmentation seen as a side effect post treatment. Although the pathophysiology of post burn hypopigmentation remains obscure, studies investigating changes in excisional wounds suggest that scar tissue laid down after healing by secondary intention provides a barrier not only to the transfer of melanin by the dendritic processes but also to the melanocyte migration with resultant hypopigmentation usually permanent particularly in dark skinned individuals [10], as in our case. Whether the hypopigmented patches were a side effect of our treatment or post burn healing sequelae in our dark skinned infant not been established.

Learning Points

The polyethylene drape used to prevent evaporative heat loss from the skin of the extremely premature infant should be removed from underneath the infant before skin asepsis is obtained during procedures to prevent pooling of residual chlorhexidine solution and heating of this pooled solution from the overhead radiant warmer. Early detection with irrigating the burned areas of skin with normal saline would likely have reduced the progression of the injury.

Use of Silicone dressing gel along with silicone impregnated dressing was beneficial and appeared safe to use in the treatment of chemical burns on the skin of this extremely premature infant in this study

Further research is required to obtain superior evidence of its efficacious and safe use in the treatment of skin burns in extremely premature infants.

References

1. Brett DW (2006) A review of moisture-control dressings in wound care. *J Wound Ostomy Continence Nurs* 33: S3-S8.
2. Medhi B, Sewal RK, Kaman L, Kadhe G, Mane A (2013) Efficacy and safety of an advanced formula silicone gel for prevention of post-operative scars. *DermatolTher* 3: 157-67.
3. Taquino L (2000) Promoting wound healing in the neonatal setting: Process versus protocol *J Perinat Neonatal Nurs* 14: 104-18.
4. Mustoe T (2008) Evolution of silicone therapy and mechanism of action in scar management. *Aesth Plast Surg*. 32: 82-92.
5. Hanasono MM, Lum J, Carroll LA, Mikulec AA, Koch RJ (2004) The effect of silicone gel on basic fibroblast growth factor levels in fibroblast cell culture. *Arch Facial Plast Surg* 6: 88-93.
6. Bingué Espuny X, Soria X, Solé E, Garcia J, Marco JJ, et al. (2010) Chlorhexidine-methanol burns in two extreme preterm newborns. *PediatrDermatol* 27: 676-678.
7. Kutsch J, Ottinger D (2014) Neonatal skin and chlorhexidine: a burning experience. *Neonatal Netw* 33: 19-23.
8. Lashkari HP, Chow P, Godambe S (2012) Aqueous 2% chlorhexidine-induced chemical burns in an extremely premature infant. *Arch Dis Child Fetal Neonatal Ed* 97: F64.
9. Sivathasan N, Ramamurthy N, Pabla RS (2010) Chemical burns associated with chlorhexidine-alcohol solution: an avoidable complication? *J Burn Care Res* 31: 833.
10. Grover R, Morgan BDG (1996) Management of hypopigmentation following burn injury. *Burns* 22: 627-30.

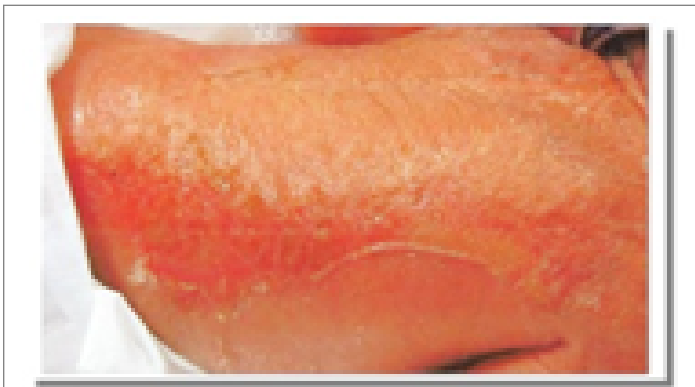

Figure 2: clinical improvement seen on the lesions of the burns 96 hours after the commencement of treatment with silicone gel covered with silicone impregnated dressing

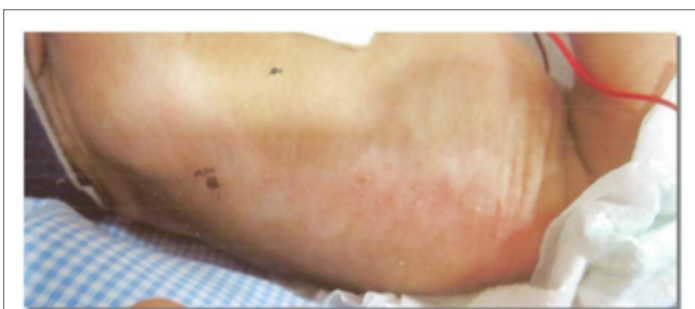


Figure 3: complete healing of the skin at the areas of the previous burns