

Apoplexy along with Spinal Cord Injury - A rare Combination

Dildip Khanal*

Siddhi Vinayak Aspatal & Prasuti Griha Pvt. Ltd, Gongabu Chowk, Kathmandu, Nepal

Corresponding author: Dildip Khanal, HOD of Physiotherapy Department, Siddhi Vinayak Aspatal & Prasuti Griha Pvt. Ltd, Gongabu Chowk, Kathmandu, Nepal, **E-mail:** dildip17@gmail.com

Received date: 28 March, 2015; **Accepted date:** 28 May, 2015; **Published date:** 31 May, 2015.

Citation: Khanal D (2015) Apoplexy along with Spinal Cord Injury - A rare Combination. *J Neurol Neurobiol* 1(2): doi <http://dx.doi.org/10.16966/2379-7150.106>

Copyright: © 2015 Khanal D. This is an open-access article distributed under the terms of the Creative Commons Attribution License, which permits unrestricted use, distribution, and reproduction in any medium, provided the original author and source are credited.

Abstract

Apoplexy and the spinal cord injury are the most common neurological disorders, representing foremost causes of disability. Nevertheless, a combination of the diseases is a rare life-threatening condition requiring a team of rehabilitation for management.

Keywords: Apoplexy; Spinal cord injury; Therapeutic rehabilitation

Background

“Apoplexy”, “cerebral vascular accident” or “brain attack” are the frequently and alternatively used terms for stroke [1,2]. Most cerebrovascular diseases are manifested by abrupt onset of a focal neurological deficit, as if the patient was “struck by hand of God” [3]. World Health Organization defined stroke as “acute onset of neurological dysfunction due to abnormality in cerebral circulation of resultant signs and symptoms that corresponds to involvement of focal area of brain lasting more than 24 hours” [4]. As a result, the affected area of the brain is unable to function showing clinically a variety of focal deficits such as changes in the level of consciousness and impairments of sensory, motor, cognitive, perceptual and language function [5]. Hence, the need of comprehensive rehabilitation teams following such conditions cannot be neglected. Among them, therapeutic rehabilitation plays an integral part. In addition, when one is even having an associated life-threatening condition such as spinal cord injury, the rehabilitation of such a person depicts challenges to physiotherapy. Here is a description of such a rare case.

Case Report

54 years old male, the manager by occupation with a clinical diagnosis of right cerebrovascular accident since two months reported to Physiotherapy Department with the complaint about difficulty in moving his lower limbs and difficulty in performing activities of daily living independently.

His past history revealed that he was having traumatic cervical spinal cord injury leading to quadriplegia since eleven years. Also he was suffering from hypertension and diabetes mellitus since fifteen years. Surgical history showed that he was operated on spinal cord injury to anterior approaches C5-6 disectomy and fusion with cloward technique. Neurological examination showed that his superficial, deep and cortical sensations were intact up to the dermatome level T12. Muscle tone of the right upper limb was hypertonic with the grade 1+ spasticity according to Modified Ashworth Scale (MAS) while the tone of the left upper limb was also hypertonic with the grade 2 spasticity. The muscle tone of the bilateral lower limb was hypertonic with the grade 3 spasticity. His deep tendon reflexes were exaggerated for the bilateral upper and lower limbs. Plantar response was extensor (Babinski positive) for bilateral legs. Voluntary Control Grading (VCG) for right upper limbs was 5 while 2 for the lower

limbs. For the left upper limbs, VCG was 3 while for the lower limbs it was 0 [5].

The investigatory findings on Magnetic Resonance Imaging (MRI) of a brain revealed acute infarct in Pons on right sides, few ischemic foci noted in fronto-parietal white matter regions on both sides and changes of mastoiditis on left side (Figure 1). Impressions of angiography revealed hypoplastic right vertebral arteries, non-visualization of flow in A1 segment of anterior cerebral artery on left side and hypoplastic posterior communicating arteries on both sides. Impressions of MRI of whole spine showed mild degenerative disc disease at C3-5 and L5-S1 levels and an area of altered signal intensity in the cord at level of C5 vertebra in the mid sagittal section (Figure 2).

Discussion

The stroke along with the spinal cord injury is a catastrophic condition that depends on its severity, may cause dramatic changes in the victim's life. The effects of such condition have an impact not only on the lives of the victim's but also on the family and the society as a whole. The patients need a well-coordinated, specialized rehabilitation programs consisting of a team of physicians and the health care professionals to provide the

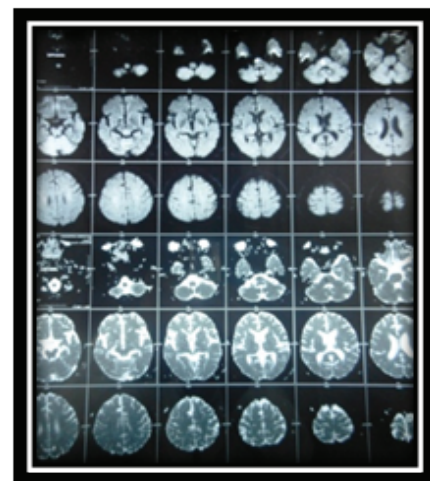


Figure 1: MRI of brain showing infarct on Pons

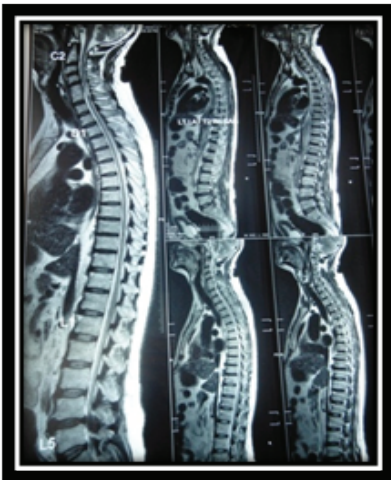

Figure 2: MRI of Spinal Cord showing mild degenerative disc disease at C3-5 and L5-S1 levels and C5-6 disectomy and fusion

tools necessary to develop a satisfying and productive post disease/injury lifestyle. Physiotherapeutic rehabilitation following such condition includes prevention of secondary complications from bedsores, pulmonary complication, deep vein thrombosis, autonomic dysreflexia etc.; postural reeducation and positioning; maintenance of muscle property and joint range of motion; retraining for bed mobility, activities of daily living and transfer techniques; relaxation techniques; management of bowel and bladder. Educating the patient and his family members of the condition

and its prognosis [5-8]. The above allusion therapeutic interventions have been found to be fruitful during the course of rehabilitation.

Conclusion

Rehabilitation of such an appalling condition is not the job of one's person. Therefore, the coordination among the various teams of rehabilitation plays an essential role in making the life of such victim's gratifying.

References

1. Thompson JE (1996) The evolution of surgery for the treatment and prevention of stroke. *The Willis Lecture. Stroke* 27(8): 1427-1434.
2. Kopito Jeff (2001) *A Stroke in Time*. 6(9).
3. Dan L Long, Anthony S Fauci, Dennis L Kasper, Stephen L Hauser, J Larry Jameson, et al. (2012) *Harrison's principle of internal medicine*. (18thedn), Mc Graw Hill, USA.
4. World Health Organization (1978) *Cerebrovascular Disorders* Geneva: World Health Organization.
5. Susan B O'Sullivan, Thomas J Schmitz (2007) *Physical Rehabilitation*. (5thedn), Jaypee Brothers Medical Publishers (P) Ltd, New Delhi, India.
6. Ida Bromley (2006) *Tetraplegia and Paraplegia. A guide for physiotherapists*. (6thedn), Elsevier Ltd, UK.
7. Darcy A. Umphred (2001) *Neurological Rehabilitation*. (4thedn), Mosby, An affiliate of Elsevier Ltd, UK.
8. Thomas N Bryce (2010) *Spinal Cord Injury*. (1stedn), Demos Medical Publishing, New York, USA.