

## Thoracic Paravertebral Abscess and Secondary Meningitis in a Hemodialysed Patients: Case Presentation

Bratescu Lavinia-Oltita<sup>1\*</sup>, Simona Stancu<sup>2,3</sup>, Gemene Marta-Emanuela<sup>1</sup>, Moga Cristina-Gabriela<sup>1</sup> and Copaceanu Diana<sup>1</sup>

<sup>1</sup>Diaverum Morarilor Nephrology and Dialysis Medical Centre, Bucharest, Romania

<sup>2</sup>“Carol Davila” University of Medicine and Pharmacy, Bucharest, Romania

<sup>3</sup>“Carol Davila” Nephrology Hospital, Bucharest, Romania

\*Corresponding author: Bratescu Lavinia-Oltita, Consultant in Nephrology, Diaverum Morarilor Nephrology and Dialysis Medical Centre, Bucharest, Romania 2A Șoseaua Morarilor, District1, Bucharest, Romania. Tel: +40-721242126; +40-21-2554212, E-mail: [lavinia\\_bratescu@yahoo.com](mailto:lavinia_bratescu@yahoo.com)

Received: 20 Nov, 2017 | Accepted: 05 Dec, 2017 | Published: 14 Dec, 2017

**Citation:** Bratescu LO, Stancu S, Gemene EM, Moga CG, Copaceanu D (2017) Thoracic Paravertebral Abscess and Secondary Meningitis in a Hemodialysed Patients: Case Presentation. J Network Med Target Ther 1(1): [dx.doi.org/10.16966/2577-1906.102](http://dx.doi.org/10.16966/2577-1906.102)

**Copyright:** © 2017 Bratescu LO, et al. This is an open-access article distributed under the terms of the Creative Commons Attribution License, which permits unrestricted use, distribution, and reproduction in any medium, provided the original author and source are credited.

### Abstract

There was presented a case of thoracic paravertebral abscess and secondary meningitis in chronic hemodialysed (HD) patients, related to central venous catheter (CVC) use.

Clinical symptoms, including those that signify a bacteraemia, appeared in a patient with much co-morbidity, after 7 days from CVC replacement. They have not highlighted infection signs at exit site CVC. Neurological signs and symptoms occurred after 5 days of intensive antibiotic treatment. Secondary meningitis is a relatively rare complication of catheter-related bloodstream infection. The presented case has particularities in evolution before and after the start of antibiotic therapy. *Clostridium difficile*-associated diarrhea has made difficult the management of antibiotic treatment.

**Keywords:** Hemodialysis; Abscess; Meningitis; Catheter

### Introduction

Catheter-related bloodstream infections (CRBSIs), exit-site infection, tunnel infections and bacteraemias are common complications related to hemodialysis central venous catheter use and present high morbidity, mortality and costs [1,2]. Bacteraemias are the most clinically important due to potential to transform into sepsis [1,3]. The prevalent central venous catheter (CVC) use in patients initiated in hemodialysis (HD) has increased to ~25% while >80% in some countries, despite

recommendations of professional organizations to limit such use [3]. Usually, metastatic infectious complications of CRBSIs include endocarditis, osteomyelitis, spinal epidural abscess, septic arthritis, brain abscess, and septic pulmonary emboli [3,4]. The most common causative pathogens are gram-positive bacteria, with *Staphylococcus aureus* and coagulase-negative staphylococci accounting for 40% to 80% of CRBSIs [3-6].

### Materials and Methods

A 67-year-old woman with insulin-dependent diabetes mellitus, severe vascular lesions (anterior myocardial infarction, aortocoronary by-pass, left thigh amputation), secondary hypertension, CKD stage 5, is HD initiated by right jugular tunneled CVC in 2015 (Figure 1). Due to vascular quality and particularity, the patient also presents two unsuccessful CVC implants. The last malfunctioning CVC is replaced in 2017 and after 7 days, the patient accuses intense posterior chest pain and fever, without infection signs at exit site CVC, with suspicion of infectious discitis. RMN and CT spine scan have been highlighted paravertebral abscess T3-T5 in contact with right pleura (Figure 2-4), without neurosurgical indication. Para clinically have been highlighted marked inflammatory syndrome, positive *Staphylococcus aureus* blood culture. After 5 days of treatment with Vancomycin, Rifampicin, and Ceftriaxone, according to the guides, the febrile syndrome persists and spatial and temporal disorientation together with cervical and thoracic spine stiffness is being installed. Diagnosis of *Staphylococcus aureus* meningitis was established by cerebrospinal fluid examination. Transesophageal ultrasound excluded bacterial endocarditis. It was initiated 14 days of treatment with intravenous Linezolid 600mg/day, together with intravenous Vancomycin 500 mg/ HD session and oral Rifampicin 600 mg/day - 6 weeks. We use taurolidine as lock post-dialysis CVC and antimicrobial solution. After 48 hours of treatment, the patient was afebrile and the neurological signs and symptoms were reduced. Clinical evolution was favorable with improved

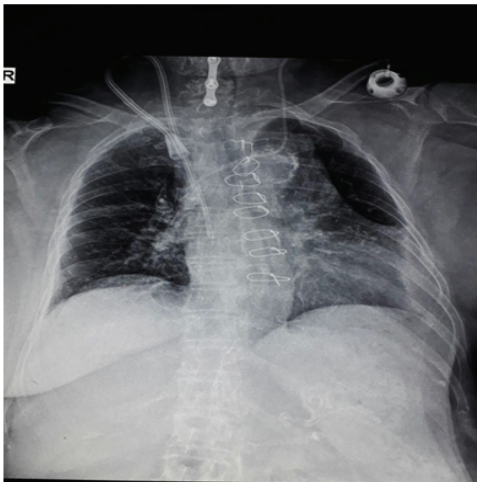


Figure 1: Anterior myocardial infarction, aortocoronary by-pass, left thigh amputation

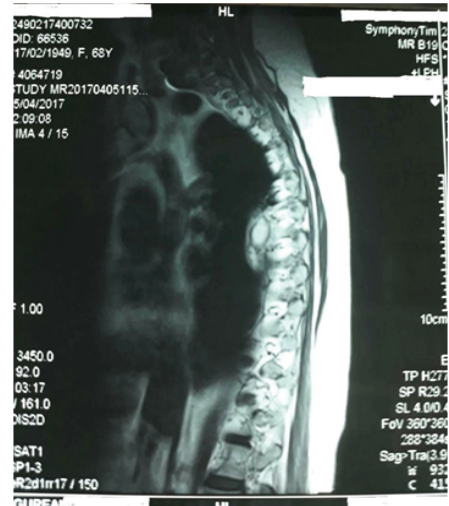

Figure 4: RMN and CT spine scan

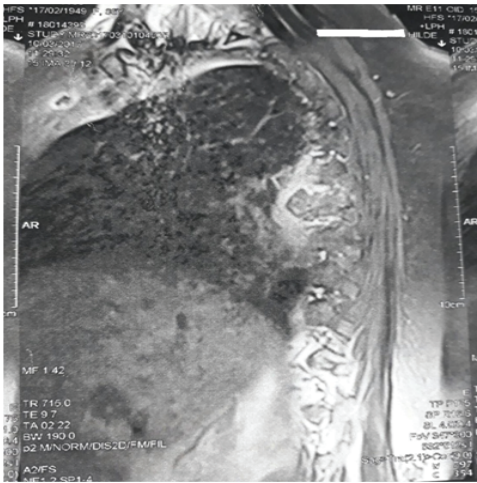


Figure 2: RMN and CT spine scan

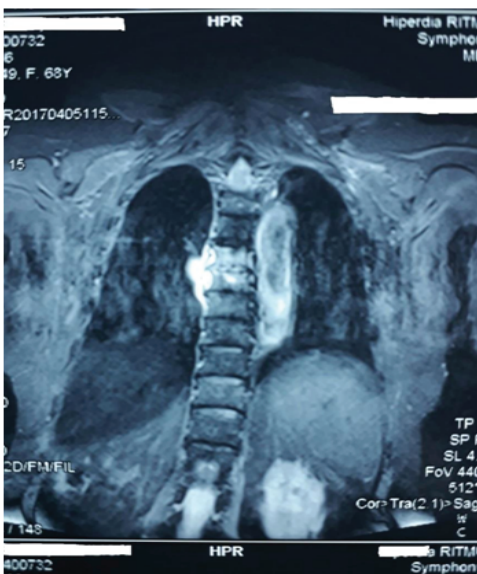


Figure 3: RMN and CT spine scan

paraclinical parameters: cerebrospinal fluid cellularity after 2 weeks of antibiotics did not highlight any changes and repeating MRI had made significant improvements. During intensive antibiotic therapy, the patient presents, in addition, *Clostridium difficile*- associated diarrhea, treated with oral vancomycin in lower doses and on alternate days. After the 6 weeks of treatment, the patient was considered to be cured.

### Discussion and conclusion

Bacteremic episodes in hemodialysis patients with long-term tunneled catheters are related to the presence of diabetes, peripheral atherosclerosis, a previous history of bacteremia, nasal carriage of *S. aureus*, longer catheter use duration, higher total intravenous iron dose and local infection [3]. Gram-positive organisms are the most common cause of catheter-related infections, with both coagulase-negative staphylococcus and *S. aureus* accounting for the majority of cases [3]. *Enterococci*, aerobic gram-negative rods, and fungal species are also involved.

Initial empiric therapy is necessary and based on the severity of disease, risk factors for infection, and the likely pathogens. Vancomycin is recommended as first-line therapy in those hospitals with an increased incidence of methicillin-resistant *staphylococci* [3] and additional empiric should coverage for gram-negative organisms with an aminoglycoside or cephalosporin, especially in patients who are severely ill [3]. Medications should be adjusted after culture and sensitivity results are known.

In this case, the bacteremic episode could be related to a malfunctioning catheter that was replaced or contamination during catheter replacement, as a medical technique error.

Our case particularity is represented by its complexity through the two relatively rare complications-paravertebral abscess and secondary meningitis, in patient with much comorbidity. Due to the absence of any another way of vascular

access, it was decided to keep the catheter just replaced. Many studies have evaluated attempted catheter salvage using intravenous (IV) antibiotics alone and have shown varying success rates [3]. We use taurolidine as lock post-dialysis CVC and antimicrobial solution. Logistical challenges such as lock preparation procedures, use of additives (e.g. heparin, citrate, or ethylenediaminetetraacetic acid), the timing of initiation and therapy duration, optimal dwell time and catheter accessibility, and risks of antibiotic lock therapy (ALT) are also described in the literature and development of local protocols is recommended in order to avoid these potential barriers [7]. Considering these, ALT was not used.

The combination of antibiotics has been used according to the antibiogram and severity of complications. Simultaneous administration of intravenous and oral Vancomycin for bacteremia and *Clostridium difficile* treatment is also relatively rare.

CRBSIs are a major cause of hospitalization and mortality in hemodialysis patients.

Every dialysis program should have an infection surveillance program with dedicated personnel and resources, to facilitate identification of catheter-related infections and timely interventions to reduce infection rates and improve patient clinical outcomes [8].

### Conflict of Interest

The authors declare that they have no conflict of interest.

### References

1. Lisa M Miller, Edward Clark, Christine Dipchard, Swapnil Hiremath, Joanne Kappel, et al. (2010) Hemodialysis Tunneled Catheter-Related Infections. *Can J Kidney Health Dis* 3: 1-11.
2. Ramanathan V, Chiu EJ, Thomas JT, Khan A, Dolson GM, et al. (2007) Healthcare costs associated with hemodialysis catheter-related infections: a single-center experience. *Infect Control Hosp Epidemiol* 28: 606-609.
3. Tracie A Wilcox (2005) Catheter-Related Bloodstream Infections. *Semin Intervent Radiol* 26: 139-143.
4. Nissenson AR, Dylan ML, Griffiths RI, Yu HT, Dean BB, et al. (2005) Clinical and economic outcomes of *Staphylococcus aureus* septicemia in ESRD patients receiving hemodialysis. *Am J Kidney Dis* 46: 301-308.
5. Danese MD, Griffiths RI, Dylan M, Yu HT, Dubois R, et al. (2006) Mortality differences among organisms causing septicemia in hemodialysis patients. *Hemodial Int* 10: 56-62.
6. Taylor G, Gravel D, Johnston L, Embil J, Holton D, et al. (2004) Incidence of bloodstream infection in multicenter inception cohorts of hemodialysis patients. *Am J Infect Control* 32: 155-160.
7. Justo JA, Bookstaver BP (2014) Antibiotic lock therapy: review of technique and logistical challenges. *Infect Drug Resist* 7: 343-363.
8. Mermel LA, Farr BM, Sheretz RJ, Raad II, O'Grady N, et al. (2001) Guidelines for the management of intravascular catheter-related infections. *Clin Infect Dis* 32: 1249-1272.