

# A Modified Impression Technique for Aesthetic Restoration of Multiple Dental Implants in the Anterior Area Using Provisional Prosthesis as Impression Coping

Amar Bhochhibhoya\*

Assistant Professor, Department of Prosthodontics, Nepal Medical College, Kathmandu, Nepal

\*Corresponding author: Amar Bhochhibhoya, Assistant Professor, Department of Prosthodontics, Nepal Medical College, Kathmandu, Nepal, E-mail: amarbhochhibhoya@gmail.com

Received: 07 May, 2020 | Accepted: 12 May, 2020 | Published: 19 May, 2020

**Citation:** Bhochhibhoya A (2020) A Modified Impression Technique for Aesthetic Restoration of Multiple Dental Implants in the Anterior Area Using Provisional Prosthesis as Impression Coping. *Int J Dent Oral Health* 6(5): dx.doi.org/10.16966/2378-7090.326

**Copyright:** © 2020 Bhochhibhoya A. This is an open-access article distributed under the terms of the Creative Commons Attribution License, which permits unrestricted use, distribution, and reproduction in any medium, provided the original author and source are credited.

## Abstract

Transferring emergence profile and gingival architecture to a definitive cast is essential to achieve a superior and predictable esthetic outcome with implant-supported fixed restorations. This article describes a simplified and economical technique that accurately preserves the soft-tissue profile which involves the use of an interim prosthesis as impression coping for the final impression.

**Keywords:** Emergence profile; Soft tissue molding; Implant-supported fixed restorations

## Introduction

The restoration of missing anterior teeth with implant-supported fixed prosthesis poses an esthetic challenge in patients with high smile line, particularly when there is loss of gingival volume [1,2]. Obtaining a well contoured restoration with an appropriate emergence profile and gingival architecture that harmonizes with the adjacent natural teeth is difficult in such cases [3].

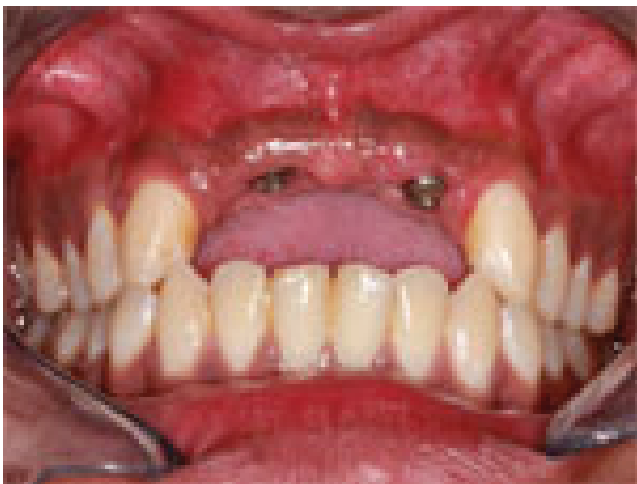When multiple teeth are missing there is resorption of the adjacent alveolar bone which results in loss of soft tissue that obliterates the interdental papilla [4-6]. The correction of soft tissue volume to improve esthetics requires multiple surgical procedures, which may not be possible in some cases [1]. Gingival conditioning with the use of an interim prosthesis can help in enhancing shape and contour of peri-implant gingival and soft tissue under pontic sites which avoids additional corrective surgeries [4,7-10]. The proper gingival configuration not only mimics natural emergence profile but also ensures ideal adaptation of the surgical and prosthetic components, significantly influences the health of peri-implant tissues and also helps in the maintenance of proper oral hygiene [3,10]. The customized interim prosthesis helps in the molding of the soft tissues to achieve exact cervical contour and emergence profile of the planned final prosthesis [11]. Gingival tissue remodeling by selective pressure application is an easy and non-traumatic way to enhance gingival architecture [12].

The peri-implant soft tissue collapses and shrinks after removal of the interim prosthesis which precludes transfer of the intraoral soft tissue architecture to the definitive cast. The prefabricated stock impression copings do not take into account soft tissue morphology

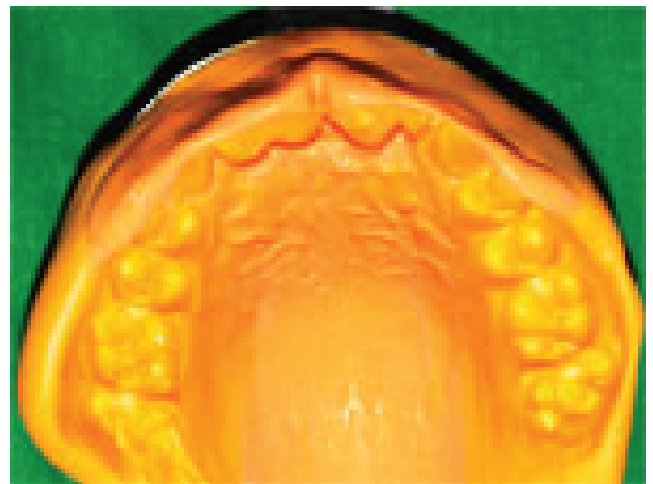formed by interim restorations [3,13]. Several modified impression techniques have been reported for the accurate transfer of information regarding the soft tissues [13,14]. This article describes a simplified impression technique that preserves the soft-tissue profile of both peri-implant and pontic sites gained after gingival conditioning with interim implant-supported fixed dental prosthesis.

## Technique

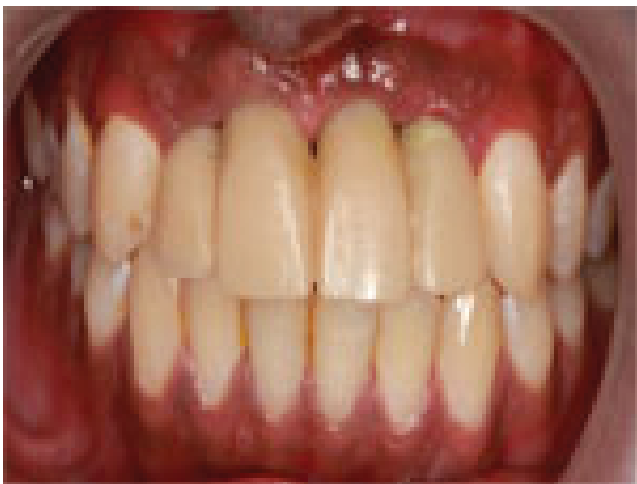1. After soft tissue conditioning with interim implant-supported fixed dental prosthesis, peri-implant and pontic sites were molded and guided to achieve the desired emergence profile which demonstrated adequate healing for an impression to be made (Figures 1-3).
2. Make a putty wash impression over the interim implant-supported fixed dental restoration with polyvinyl silicone impression material (EliteHD+, Zhermack, Germany). Remove the impression after it is set and check for the accuracy (Figure 4).
3. Remove the interim prosthesis and place the healing abutment. Inject polyvinyl silicone impression material around the healing abutment and pontic site to maintain the soft-tissue contour.
4. Secure implant analogues to the interim prosthesis and reposition the prosthesis in the set polyvinyl silicone impression (Figure 5).
5. Inject rubber gingival replication material (Gingitech, Ivoclar Vivadent, Lichtenstein) into the impression. After polymerization, subsequently pour the impression in Type IV dental stone (Kalarock, India) to form the definitive cast (Figure 6). The gingival soft tissue contour was transferred to the definitive cast which allowed easy cervical contouring of the final restoration (Figure 7).



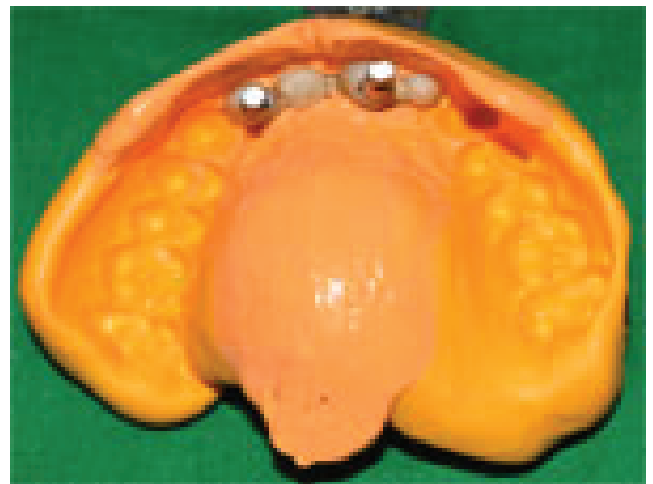**Figure 1:** Initial tissue architecture showing obliteration of interdental papilla.



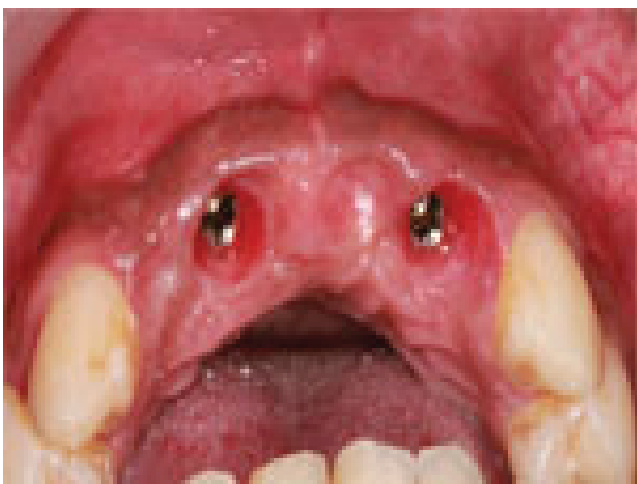
**Figure 4:** Polyvinyl silicone impression made over interim prosthesis.



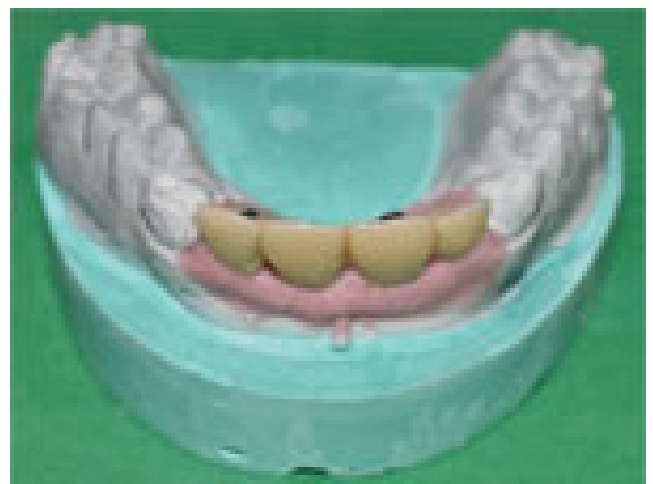**Figure 2:** Customized interim fixed prosthesis.



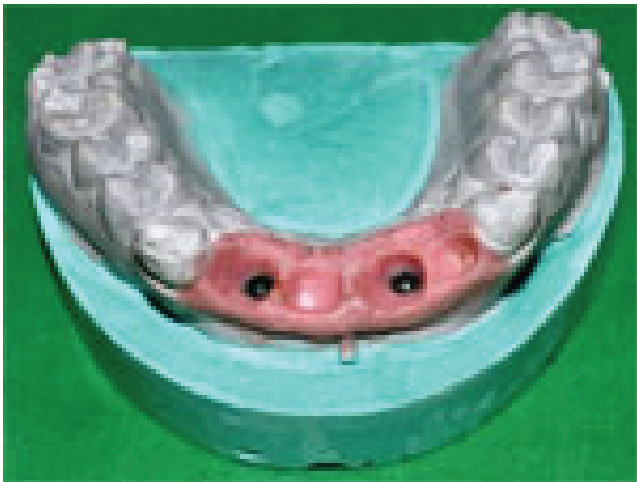**Figure 5:** Interim prosthesis seated in the impression.



**Figure 3:** Gingival contour after soft tissue molding.



**Figure 6:** Retrieval of definitive cast.



**Figure 7:** Soft tissue architecture and emergence profile transferred to the definitive cast.

## Discussion and Conclusion

The presented technique allows easy and accurate transfer of molded soft-tissue contour of peri-implant and pontic sites to the definitive cast which helps in achieving predictable esthetic outcome. In this technique, the interim restoration itself is used as impression coping. This technique is straight forward, economical and requires minimum armamentarium. The cervical contour of the planned final prosthesis is identical with that of the customized interim prosthesis which minimizes chances of soft-tissue distension during insertion of final prosthesis. The major drawback of this technique is that the patient has to remain without provisional restoration until the definitive cast is made which poses the risk of collapse of the soft tissues.

## References

1. Wöhrle PS (2003) Nobel Perfect esthetic scalloped implant: rationale for a new design. *Clin Implant Dent Relat Res* 5: 64-73.
2. Attard N, Barzilay I (2003) A modified impression technique for accurate registration of peri-implant soft tissues. *J Can Dent Assoc* 69: 80-83.
3. Yiqing H, Yuting H, Wang J (2018) A technique to record the gingival configuration of an interim implant-supported fixed partial denture. *J Prosthet Dent* 120: 495-497.
4. Lam RV (1960) Contour changes of the alveolar process following extractions. *J Prosthet Dent* 10: 25-32.
5. Saadoun AP, Touati B (2007) Soft tissue recession around implants: is it still unavoidable?--Part II. *Pract Proced Aesthet Dent* 19: 81-87.
6. Rompen E, Raepsaet N, Domken O, Touati B, Van Dooren E (2007) Soft tissue stability at the facial aspect of gingivally converging abutments in the esthetic zone: a pilot clinical study. *J Prosthet Dent* 97: 119-125.
7. Kan JY, Rungcharassaeng K, Lozada J (2003) Immediate placement and provisionalization of maxillary anterior single implants: 1-year prospective study. *Int J Oral Maxillofac Implants* 18: 31-39.
8. Lefkove MD, Beals RP (1990) Immediate loading of cylinder implants with overdentures in the mandibular symphysis: the titanium plasma-sprayed screw technique. *J Oral Implantol* 16: 265-271.
9. Babbush CA, Kent JN, Misiak DJ (1986) Titanium Plasma-sprayed (TPS) screw implants for the reconstruction of the edentulous mandible. *J Oral Maxillofac Surg* 44: 274-282.
10. Davarpanah M, Martinez H, Celletti R, Tecucianu JF (2001) Three-stage approach to aesthetic implant restoration: emergence profile concept. *Pract Proced Aesthet Dent* 13: 761-767.
11. Ganddini MR, Tallents RH, Ercoli C, Ganddini R (2005) Technique for fabricating a cement-retained single-unit implant-supported provisional restoration in the esthetic zone. *J Prosthet Dent* 94: 296-298.
12. Neves FD, Silveira-Júnior CD, Coró V, Silva-Neto JP, Simamoto-Júnior PC (2013) Gingival conditioning in an implant-supported prosthesis: a clinical report. *J Oral Implantol* 39: 483-485.
13. Chee W, Jivraj S (2006) Impression techniques for implant dentistry. *Br Dent J* 201: 429-432.
14. Azer SS (2010) A simplified technique for creating a customized gingival emergence profile for implant-supported crowns. *J Prosthodont* 19: 497-501.