

## Vessel Sealing Bipolar may Contribute to Safety Bloodless Resection for the Patients with Hemangioma of the Tongue

Koji Kawaguchi<sup>1\*</sup>, Akihisa Horie<sup>2</sup>, Tomoyuki Saito<sup>3</sup>, Naoki Iida<sup>4</sup>, Mami Suzuki<sup>5</sup>, Kuniaki Haneji<sup>6</sup> and Yoshiki Hamada<sup>1</sup>

<sup>1</sup>Department of Oral and Maxillofacial Surgery, School of Dental Medicine, Tsurumi University, Japan

<sup>2</sup>Department of Oral and Maxillofacial Surgery, Kanto Rosai Hospital, Japan

<sup>3</sup>Department of Oral and Maxillofacial Surgery, Nagano Matsushiro General Hospital, Japan

<sup>4</sup>Department of Oral and Maxillofacial Surgery, Ozawa Hospital, Japan

<sup>5</sup>Department of Oral and Maxillofacial Surgery, Syonann Tobu General Hospital, Japan

<sup>6</sup>Haneji Oral and Maxillofacial Surgical Clinic, Japan

**\*Corresponding author:** Koji Kawaguchi, DDS, PhD, Associate Professor, Department of Oral and Maxillofacial Surgery, School of Dental Medicine, Tsurumi University, 2-1-3, Tsurumi, Tsurumiku, Yokohama, 2308501 Japan, Tel: 81-45-580-8521; Fax: 81-45-581-0024; **E-mail:** [kawaguchi-k@tsurumi-u.ac.jp](mailto:kawaguchi-k@tsurumi-u.ac.jp)

**Received date:** 30 Aug 2017; **Accepted date:** 18 Sep 2017; **Published date:** 22 Sep 2017.

**Citation:** Kawaguchi K, Horie A, Saito T, Iida N, Suzuki M, et al. (2017) Vessel Sealing Bipolar may Contribute to Safety Bloodless Resection for the Patients with Hemangioma of the Tongue. *Int J Dent Oral Health* 3(5): doi <http://dx.doi.org/10.16966/2378-7090.242>

**Copyright:** © 2017 Kawaguchi K, et al. This is an open-access article distributed under the terms of the Creative Commons Attribution License, which permits unrestricted use, distribution, and reproduction in any medium, provided the original author and source are credited.

### Abstract

Recently, clinical usefulness of using LigaSure™ system with vessel-sealing devices and the Valleylab™ electrode knife (Covidien, USA) for head and neck cancer surgery was widely reported. These devices were used to resection of small hemangioma for 71 and 78 year-old women with small hemangiomas of the lateral surface of the tongue. The resection by LigaSure™ system for the treatment of small tongue hemangioma was bloodless and short-time surgery with no complication.

**Keywords:** Vessel-sealing; Bipolars; LigaSure™; Hemangioma; Vessel lesion; Tongue

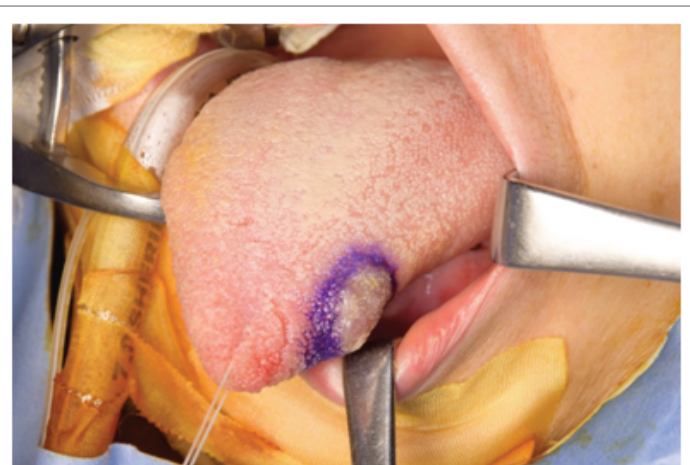
### Introduction

Hemangioma is a benign tumor of dilated blood vessels. It is commonly seen in the head and neck region but rarely in the oral cavity. Hemangiomas require appropriate treatments with controlled intra-operative bleeding, especially in the oral cavity [1]. LigaSure™ Small jaw (LSSJ) (Covidien, USA) is one of the novel vessel sealing devices. LSSJ is used to seal vessels and tissue for safe resection in head and neck surgery [2,3]. LSSJ system is a safe, effective, and time-saving piece of equipment for use during parotid gland surgery. The vessel sealing system applies a precise pressure and energy for transformation of the collagen and elastin within vessel walls and forming a permanent sealing. Our result of the harvesting a pectoral is major cutaneous flap using the LigaSure™ Impact vessel-sealing device was excellent on the viewpoint of for small quantity of intra-operative bleeding [3].

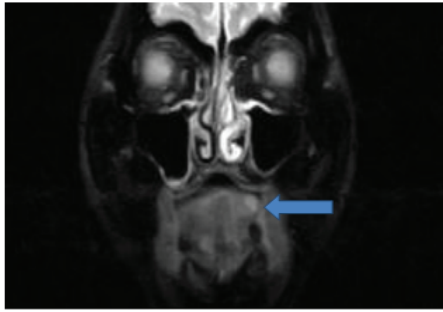
### Technical Note

Recently, we tried to use LSSJ for resection of small tongue hemangioma in 2 patients. They were 71 and 78 year-old women with small hemangiomas of the lateral surface of the tongue. Their lesions were enlarged slowly in the recent few years, however, there were no history of associated pain or bleeding from the site. Their sizes were measuring of 18 × 16 mm (Figures 1 and 2) and 20 × 17 mm (Figures 3 and 4) on these MR images, respectively. As these lesions were clearly shown by MR images, ultrasonography was not done. Hypertension was observed with both patients. Under general anesthesia, 3.0-ml 2% Lidocain without adrenalin was used to prevent the hemangioma from shrinkage. LigaSure™ Valleylab Mode, mixture cutting and coagulation mode, electric cautery (LSVEC) (Covidien, USA) attached a needle tip with a fine point was used to incise the surface of the margin of hemangioma (Figures 5 and

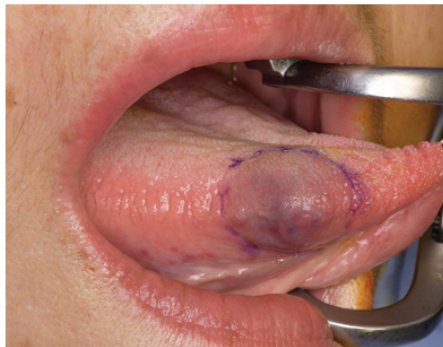6). Then, the hemangiomas were completely resected by LSSJ with secure sealing and cutting of the surrounding muscle including invisible microveins. Major nutrient vessels of the tumors were not observed (Figures 7 and 8). The time required for resection and suturing were around 10 minutes, and blood loss were extremely small amount of 1 g. Each wound was closed by 4/0 absorbable and nylon surgical suture. Postoperative local complications were not observed, and wound healing was good. At 1-week postoperative follow-up, the symmetry of the tongue was confirmed (Figures 9 and 10). Both histopathological reports confirmed the diagnosis of cavernous hemangioma. Patients were obtained for this publication.



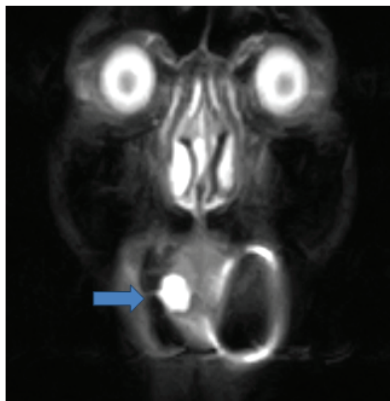
**Figure 1:** Isolated hemangioma on the left side of the tongue.



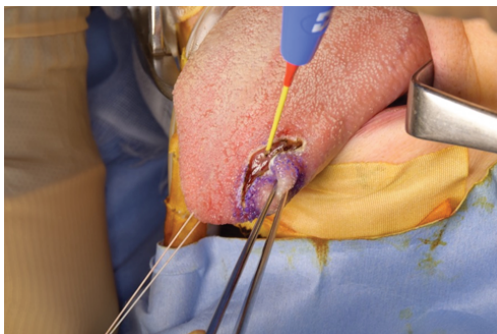
**Figure 2:** MR image of the hemangioma (18 × 16 mm) located on the left side of the tongue in coronal plane.



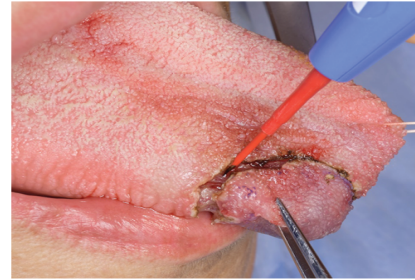**Figure 3:** Isolated hemangioma on the right side of the tongue.



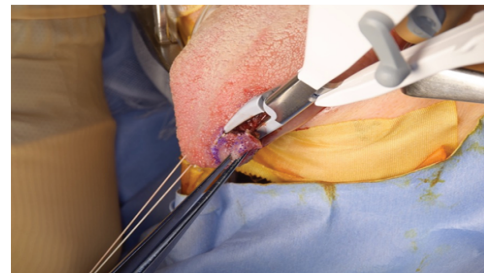
**Figure 4:** MR image of the hemangioma (20 × 17 mm) located on the right side of the tongue in coronal plane.



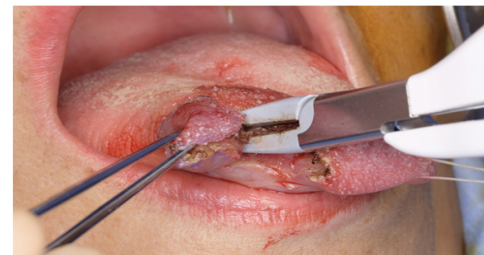**Figure 5:** Incision the surface layer of the periphery of hemangioma by LigaSure ValleylabMode™ (mixture cutting and coagulation mode) electric cautery (LSVEC) (Covidien, USA) with a straight needle tip.



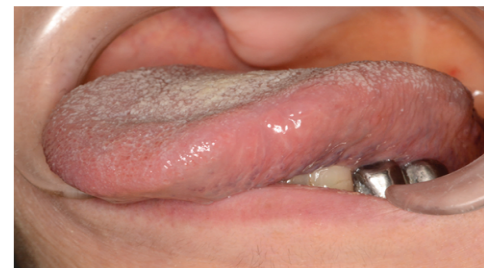**Figure 6:** Incision the surface layer of the periphery of hemangioma by LigaSure ValleylabMode™ electric cautery with a straight needle tip.



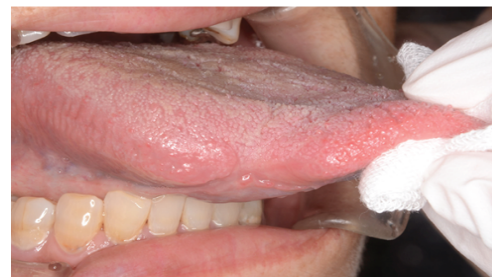**Figure 7:** Resection by LigaSure small jaw (LSSJ) with securely sealing and cutting muscle included invisible micro-veins.



**Figure 8:** Resection by LigaSure small jaw.



**Figure 9:** At post-operative 7 days the wound was good. The symmetry of the tongue was confirmed.



**Figure 10:** At post-operative 7 days the wound was good.

## Discussion and Conclusions

The appearance of cavernous hemangioma rarely occur on the tongue. Early stage of hemangioma may be very cellular with solid nests of plump endothelial cells and little vascular lumen. It was difficult to control bleeding during surgical excision with cold knife. The tongue hemangioma requires careful consideration for consequent bleeding [1]. As a conservative treatment, intralesional laser treatment of the tongue vascular lesions was effective, however, slight paresthesia and ulcer formation were occurred as complications [4]. Regarding embolization for the treatment of the small cavernous hemangioma of the tongue, no change in the appearance and size of the mass was observed by sclerosing agent. Finally, a surgical excision was carried out [1]. Sclerotherapy remains the initial treatment of choice for symptomatic lesions, but there is a lack of reliable and comparable evidence to confirm its effectiveness and that of other treatments [5]. Plasma Knife surgery with radiofrequency (PK) was developed as a new cautery. There was no bleeding during the cauterization of the small hemangioma and no recurrence postoperatively, however, the wound healing required around three weeks [6]. The localized and superficial hemangiomas of the tongue have been treated by conventional resection with cold knife, cauterization by PK, and intralesional laser treatment. In the meantime, the resection by LSSJ and LSVEC for the treatment of small tongue hemangioma was some advantages at the points of bloodless and short-time surgery with no complication in comparison with other treatments mentioned above.

In conclusion, vessel sealing bipolar is one of the feasible device for resection of small hemangioma of the tongue.

## Fundings

The authors have no sources of funding to declare.

## Competing interests

The authors have no conflict of interest to declare.

## Ethical approval

Not required.

## Patient consent

Patients were obtained for the publication of Figures 1-10.

## References

1. Kripal K, Rajan S, Ropak B, Jayanti I (2013) Cavernous hemangioma of the tongue. *Case Reports in Dentistry* 2013: 898692.
2. Suida MI, Gallacher A, Mitchell DA (2016) Use of LigaSure™ small jaw in operations on the parotid gland: a technical note. *Br J Oral Maxillofac Surg* 54: 1040-1041.
3. Kawaguchi K, Eguchi T, Horie A, Kumagai K, Hasebe M, et al. (2016) An Immediate Reconstructive Surgery with a Pectoralis Major cutaneous Flap using the LigaSure™ Impact Vessel-sealing Device--A Technical Case Report. *Int J Dent Oral Health* 2: 158.
4. Miyazaki H, Kato J, Watanabe H, Harada H, Kakizaki H, et al. (2009) Intralesional laser treatment of voluminous vascular lesions in the oral cavity. *Oral Surg Oral Med Oral Pathol Oral Radiol Endod* 107: 164-172.
5. Fowell C, Vereá Linares C, Jones R, Nishikawa H, Monaghan A (2017) Venous malformations of the head and neck: current concepts in management. *Br J Oral Maxillofac Surg* 55: 3-9.
6. Kutluhan A, Bozdermir K, Ugras S (2008) The treatment of tongue haemangioma by plasma knife surgery. *Singapore Med J* 49: e312-e314.