

Anesthesia Management for Patients with Anti-N-Methyl-D-Aspartate Receptor Encephalitis

Yu Kang, Han Lu, Suwen Peng, Qingsheng Xue* and Buwei Yu*

Department of Anesthesiology, Ruijin Hospital, Shanghai Jiao Tong University, School of Medicine, Shanghai, China

*Corresponding authors: Qingsheng Xue, Department of Anesthesiology, Ruijin Hospital, Shanghai Jiao Tong University, School of Medicine, Shanghai, China, Tel: +8613611909184; E-mail: Xueqingshengxueyan@163.com

Buwei Yu, Department of Anesthesiology, Ruijin Hospital, Shanghai Jiao Tong University, School of Medicine, Shanghai, China, Tel: +86 13801630735; E-mail: yubuwei_2013@126.com

Received date: 10 Oct 2016; Accepted date: 26 Dec 2016; Published date: 30 Dec 2016.

Citation: Kang Y, Lu H, Peng S, Xue Q, Yu B (2016) Anesthesia Management for Patients with Anti-N-Methyl-D-Aspartate Receptor Encephalitis. J Clin Case Stu 1(6): doi <http://dx.doi.org/10.16966/2471-4925.134>

Copyright: © 2016 Kang Y, et al. This is an open-access article distributed under the terms of the Creative Commons Attribution License, which permits unrestricted use, distribution, and reproduction in any medium, provided the original author and source are credited.

Abstract

Background: Neurologic paraneoplastic syndromes rarely act as the first sign of tumors. Being an important part of neurologic paraneoplastic syndromes, anti-N-Methyl-D-Aspartate receptor encephalitis is disclosed by Josep Dalmau in 2007. It's ranked as the second autoimmune encephalitis in frequency with strong association with ovarian teratoma. Even though immunotherapy is effective, dramatic outcomes will be reached by tumor resection at the early phase. Thus there is a great challenge for anesthesiologists to manage such kind of patients. As the target of many anesthetics, NMDA receptor's function, influenced by anti-NMDA receptor antibodies, is of the first consideration when anesthesia is applied.

Case: A 15-year-old girl and a 17-year-old girl developed to a state of confusion, seizure, echolalia and paroxysmal sympathetic hyperactivity, who were suspected to have anti-NMDA receptor encephalitis and then scheduled for laparoscopic oophorectomy. According to the different states of the patients and bearing the pharmacodynamics and pharmacokinetics in mind, we made some adjustments of the anesthetics and anesthesia management applied.

Results: These patients completely recovered.

Conclusion: Enough sedation, sufficient infusion before induction and extubation under deep sedation can get rid of stress and fluctuation of circulation. Sandwich of anesthesia management can take advantage of immune suppression of sevoflurane and anti-nausea effect of propofol, which are not the main pharmacologic actions. Precise anesthesia management provides enough depth of anesthesia and analgesia that can provide satisfying muscle relaxation and reduce the usage of muscle relaxants. All of these do good to such kind of patients. Anesthesia is not only to sedate but also to treat the patients.

Keywords: Anesthesia; Anti-NMDA; Encephalitis; Ovarian teratoma

Introduction

As one of the paraneoplastic limbic encephalitis, anti-NMDA receptor encephalitis, autoimmune mediated, is disclosed by Josep Dalmau of department of neurology of university of Pennsylvania in 2007, though it had been reported since 1981. Young women (aged 14-44, median 27) are susceptible to anti-NMDA receptor encephalitis usually combined with mature cystic teratoma (approximately 54%), in addition, children and men are also described having this disorder [1]. Testicular germ cell tumor, small cell lung cancer or thymomas sometimes can lead to paraneoplastic limbic encephalitis [2]. About 86% of patients have prodromal syndrome 2 weeks prior like viral upper respiratory tract infection, and then the patients go through a multistage disorder progressing from psychiatric symptoms, memory deficits, seizures, and language disintegration into a state of unresponsiveness, catatonia and autonomic disequilibrium. Notably, 75% of patients with the anti-NMDA receptor encephalitis substantially recovered in a reverse order of the illness development [2].

Treated with first-line immunotherapy such as methylprednisolone, intravenous immunoglobulin, or plasma exchange combined with antipsychotics can efficiently control the progressed syndromes. Tumor removal can facilitate the functional recovery and get rid of the usage of second-line immunotherapy such as cyclophosphamide and/or rituximab.

The mechanism of this disease and the paroxysmal sympathetic hyperactivity of the patients are the focuses of anesthesia preparation. Many anesthetics targeted at NMDA receptor may interact with anti-NMDA receptor antibodies. And there is a need to take some special techniques and medicines to deal with the paroxysmal sympathetic hyperactivity. Only a few reports about anesthesia management for patients with anti-NMDA receptor encephalitis are available. Herein, we describe two cases caught by anti-NMDA receptor encephalitis with ovarian teratoma and discuss about the anesthesia management of such patients.

Case

A 15-year-old girl (153 cm, 46 kg) was admitted to our hospital for orofacial dyskinesia and hallucination without any significant medical history and was diagnosed as virus encephalitis primarily. Two weeks ago, she complained about headache, cough, expectoration, and pharyngalgia. With a diagnosis of virus upper respiratory tract infection in the outpatient department of the hospital, she was given some antibiotics. While the syndromes of flu were relieved, she developed numb in her limbs, and hallucination of hostility. Immediately after administration, cerebral computed tomography (CT) was taken but it was negative. Electric encephalography (EEG) showed that there were non-specific slow mixed with pike-like waves, especially in the right hemisphere. Cerebrospinal fluid

(CSF) and serum tests of antibodies were performed without any positive findings except for NMDA receptor antibody. A further study of the pelvic CT disclosed a cystic and solid mass in the rectouterine excavation. All of the results fueled the diagnosis of anti-NMDA receptor encephalitis with ovarian teratoma. She was treated with methylprednisolone, intravenous immunoglobulin, phenobarbital sodium and levetiracetam to control her psychosis and prevent the occurrence of seizure. Diazepam and sodium valproate had to be added for her developing seizure, language disintegrity, memory loss, and abnormal movement of her arms at the third day. The disorders were controlled and laparoscopic oophorectomy was scheduled at the fourteenth day.

On arrival at the operating room, she was monitored with noninvasive blood pressure, electrocardiography (ECG), pulse oximetry (SpO₂) and Narcotrend (analyses the electroencephalogram to indicate the depth of anesthesia, and the ideal value ranks from 34 to 60) with the baseline values of 122/83 mmHg, 99 bpm, 99 % and A99 respectively. 1 mg midazolam and 500 ml Lactated Ringer's Solution was delivered as soon as the peripheral vein channel was established. General anesthesia was induced with intravenous propofol (100 mg), sufentanil (15µg), rocuronium (30 mg), midazolam (0.5 mg) and dexamethasone (10 mg). One minute later, orotracheal intubation was done to facilitate the mechanical ventilation while the Narcotrend showed 34. General anesthesia was maintained with sevoflurane (2%) and intermittent infusion of sufentanil. The systolic blood pressure was maintained at the level of 70-120 mmHg, diastolic blood pressure 50-80 mmHg, heart rate 60-100 bpm, Narcotrend 40-55, and end tidal carbon dioxide pressure 33 mmHg. One cystic tumor (6 cm*5 cm*5 cm) was found in the right ovary, one (0.5 cm in diameter) in the right mesosalpinx, and another (0.4 cm in diameter) in the left mesosalpinx. Only hair and fat were there in these tumors. The pathological diagnosis was mature cystic teratoma, which accounts for 60% of benign ovarian tumors [3].

The patient emerged from anesthesia uneventfully. After autonomous respiration regained, we managed to reverse neuromuscular blockades and extubate the trachea without any complications, meanwhile Narcotrend showed 80. The patient was transported to intensive care unit (ICU) when she could respond to simple commands with the Narcotrend returned to 96. Surgery and anesthesia last for 90 minutes and 130 minutes respectively, with 50 ml of blood loss, 300 ml of urine output, and 1300 ml of total infusion volume.

During the one-day medication with methylprednisolone and sodium valproate in ICU, the patient didn't show any symptoms of the disorders and her vital signs were stable. She was transferred to the department of neurology. On the third postoperative day, she got 3 in visual analogue scale and 26 in mini-mental state examination (If scores less than 24, a person with more than 6-year education are treated as cognitive dysfunction). 10 days postoperatively, the patient was discharged from the hospital. During the two-week follow-up, the patient recovered without any presentations and any complications of anti-NMDA receptor encephalitis.

The other patient (aged 17 years old, 160 cm, 60 kg) was admitted to our hospital for coma. Three weeks earlier, she complained about headache, fever (37.8°C) and vomit. Three days after treated with antibiotics, she developed with dysphoria, difficulty of sleep, echolalia, masticatory-like movements, loss of appetite, ocular deviation, and sexually explicit behavior. Bilateral ovarian tumors were found in ultrasound (30 mm*27 mm*18 mm in the right, 4 mm in diameter in the left). Electric encephalography showed increased slow waves. Diagnosed as encephalitis, ovarian cyst, and depression, she was treated with antidepressant drugs without any amelioration. Two weeks later, the patient's psychiatric symptoms deteriorated with reduced language, apathism, and anorexia, however, the patient's CSF test, cerebral CT and MRI were normal. Antiviral therapy, anti-infective therapy and reducing

cranial hypertension were in vain. The patient developed into the state of agitation, seizure, tachycardia and coma, and then she was transferred to our hospital. Pelvic CT, ultrasound and EEG were reevaluated and NMDA receptor antibody test of CSF was done (Figure 1). The positive results of all of these tests drew the diagnosis of anti-NMDA receptor encephalitis.

Arrived at the operating room, she was monitored with life signs and Narcotrend. After aspirating gastric contents through nasogastric tube, we took out anesthesia induction with midazolam (2 mg), propofol (70 mg), sufentanil (10 µg), cisatracurium (15 mg), 2% lidocaine (20 mg) and dexamethasone (10 mg). Two minutes later, orotracheal intubation was done. General anesthesia was maintained with sevoflurane (2%) and intermittent infusion of sufentanil (30 µg totally). There were acromeric endoblast, hair and fat in the cyst found in the right, and fat only in the left (Figure 2). The pathological diagnosis was mature cystic teratoma.

The patient was sent to ICU and was extubated the next day. Then she was transferred to the department of neurology, but she was still in coma. The third day after surgery, she regained consciousness while her mini-mental state examination (MMSE) is 25 (full recovery: MMSE 29-30; mild deficits: MMSE >25-28; severe deficits). During the one-month follow up, she was completely recovered.

Discussion

Having disclosed anti-NMDA receptor encephalitis in 2007, Josep Dalmau and his fellow has made great efforts to explore the mechanism of anti-NMDA receptor encephalitis. Antibodies' bind to the subunit NR1 of NMDA receptors triggers the autophagy of NMDA receptors, decreasing the concentration of NMDA receptor on the postsynaptic membrane, and thus the GABAergic neuron comes to the dominant role of the central neuron system causing the psychosis [1]. The anti-NMDA receptor encephalitis always has autonomic instability. In Dalmau's study including 100 patients, there were 18 patients with sialorrhea and 4 with ileus which were also reported in Lang Yu's and Thomas D. Sabin's study [4,5]. Both are encountered in our case which reminds us of the need to prevent aspiration. Medications such as anticholinesterase and enough

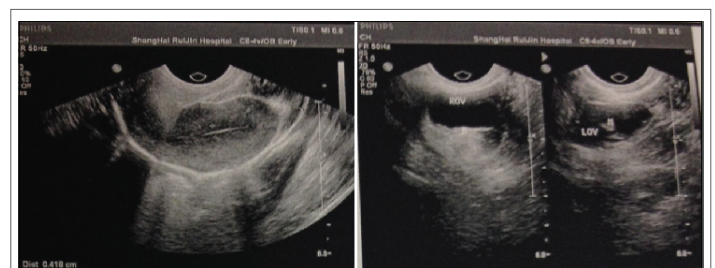


Figure 1: The result of ultrasound

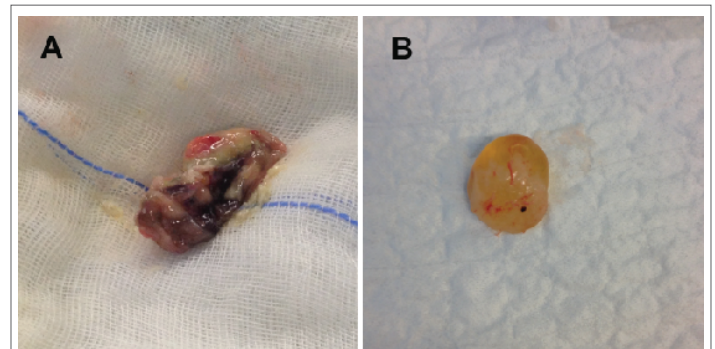


Figure 2: The cysts found. A. The taratoma in the right side. There were acromeric endoblast, hair and fat. B. The taratoma in the left side. Only fat was there

suction should be prepared. In Dalmua's study, there were 37 patients had arrhythmia (16 tachycardia, 7 bradycardia (prolonged pause and pacemakers in 4), or 14 both). The first patient has tachycardia with heart rate of 99 bpm admitted to the operating room, so compromised proposal was made that β -blocker (esmolol) was within hand and atropine abandoned. After anesthesia induction and extubation, heart rate rose up to 124 bpm and returned to less than 100 bpm after dealt with esmolol (20 mg). According to the "four-two-one" principle and the fasting time of the patients, we gave them 500 ml Lactated Ringer's Solution before induction. Sufficient infusion before induction managed to prevent the severe fluctuation of circulation.

Super families of ligand gated ion channel (such as GABA_A, glutamate, and nicotinic cholinergic receptor) and ionic glutamate receptors (such as AMPA, NMDA, and kainite receptor) are the targets of anesthetics. As the antagonist of NMDA receptor, ketamine, N₂O, tramadol, xenon and some less known anesthetics directly inhibit NMDA receptors' excitatory current [6,7]. All of them should be deprecated in the anesthesia for such patients. Propofol, a short-term hypnotic, comes into effect by elevating the intensity of transmission between GABAergic neurons. In vitro, propofol exhibits the allosteric ability to NMDA receptor, however, the dose exceeds clinical use [8]. We must bear in mind that large dose of glucocorticoids have been applied prior to surgery, which is a risk factor of propofol infusion syndrome [9]. Furthermore, sub-hypnotic dose of propofol has anti-nausea effect and anesthesia mainly with propofol can decrease the risk of nausea and vomit [10]. So propofol is still of the first choice in the anesthesia management for such kind of patients.

Although significantly reducing the exciting current of NMDA receptor, volatile anesthetics target at numbers of receptors, especially GABA_A receptor. What's more, volatile anesthetics have stronger immune suppression than propofol, and patients of anti-NMDA receptor encephalitis can take advantage of this [11]. In addition, volatile anesthetics can restrain the paroxysmal sympathetic hyperactivity. In our cases, tachycardia was controlled by esmolol until intubation. And heart rate remained normal during the anesthesia maintenance with sevoflurane without the use of esmolol. In Peter Gabriel Pryzbylowski's report, he also found that application of isoflurane or desflurane controlled autonomic instability.

NMDA receptor takes an important role in pain regulation. NMDA receptor antagonist can enhance analgesic effect of analgesics, block drug resistance and alleviate withdrawal syndrome. NMDA receptor antibody possesses the character of dissociated anesthesia of ketamine, a NMDA receptor antagonist [10,12,13]. But the pain of skin incision is the most serious pain that can cause obvious fluctuation of circulation even stroke, so we chose the minimal dose of analgesics to ensure the patients' safety and comfort. On the other hand, according to the prior and our study, the need of analgesics remains normal in these patients.

Although NMDA receptor has nothing to do with neuromuscular blockades, the characters and medication of the disease interfere with neuromuscular blockades. The increase of serum creatine kinase and myasthenia recommend that there is a necessity of reducing the use of neuromuscular blockades. Paroxysmal sympathetic hyperactivity including hypersalivation and ileus exposes the patient to the risk of aspiration and requires rapid induction of tracheal intubation. Cisatracurium and rocuronium do not impact the function of autonomic system. The former eliminates by Hoffman and the latter by liver, but the latter is fast onset of action that can meet the request of rapid induction of tracheal intubation [11]. So we applied rocuronium to the first patient. Considering there was a nasogastric tube and the stomach was empty after aspiration, we chose cisatracurium for the 17-year-old girl to facilitate the extubation in ICU. Antiemetic drugs may come into your mind. However they have some limitations. Ondansetron, for example, has a contraindication that

it can't be used to patient with gastrointestinal obstruction. Our patients have ileus, so that we don't use these antiemetic drugs. Instead we take advantage of propofol to minimize the load of kidney.

Anti-NMDA receptor encephalitis mainly affects young women. If a young woman first appeared with abnormal behavior, different diagnosis of ovarian teratoma should be considered. Early tumor resection within the first 4 months of the onset of psychosis can expedite better prognosis [1].

We get five tips to carry out the anesthesia management for anti-NMDA receptor encephalitis patients: 1) enough sedation before induction, once the peripheral vein channel is established, sedative drugs must be given to avoid the stress. 2) Sufficient infusion before induction, 500 ml Lactated Ringer's Solution or more can get rid of the severe fluctuation of circulation. 3) Sandwich of anesthesia management, anesthesia is maintained by sevoflurane and at the end of the procedure by propofol. Thus we take the advantage of immune suppression of sevoflurane and anti-nausea effect of propofol. 4) Precise anesthesia management, enough depth of anesthesia and analgesia provide satisfying muscle relaxation and reduce the usage of muscle relaxants. 5) Extubation under deep sedation, the patient would not suffer the stress and its subsequent fluctuation of circulation.

The mutual effect of anti-NMDA receptor antibodies and anesthetics makes a big challenge for anesthesiologists. With a further study of the mechanism, clinical presentation, medication, and outcome of this disease, as well as a good knowledge of anesthetic pharmacodynamics, anesthesiologists can serve a safe and convenient anesthesia for the patients, and help them with a better prognosis.

Acknowledgement

1. Shanghai Municipal Commission of Health and Family Planning, Key developing disciplines 2015.
2. Shanghai Hospital Development Center Appropriate technology of Municipal Hospital 2014.

Conflict of Interest: None.

References

1. Dalmau J, Gleichman AJ, Hughes EG, Rossi JE, Peng X, et al. (2008) Anti-NMDA-receptor encephalitis: case series and analysis of the effects of antibodies. *Lancet Neurol* 7: 1091-1098.
2. Dalmau J, Lancaster E, Martinez-Hernandez E, Rosenfeld MR, Balice-Gordon R (2011) Clinical experience and laboratory investigations in patients with anti-NMDAR encephalitis. *Lancet Neurol* 10: 63-74.
3. Tavassoli FA, Devilee P (2003) Pathology and genetics of tumours of the breast and female genital organs. Volume 5 of World Health Organization classification of tumours. Lyon, France, IARC Press.
4. Lang Y, Wang TL, Lan F, Xiao W (2014) Anesthesia management for a patient with anti-NMDA receptor encephalitis undergoing ovarian tumor resection. *Chin Med J (Engl)* 127: 2197-2198.
5. Sabin TD, Jednacz JA, Staats PN (2008) Case 26-2008: A 26-Year-Old Woman with Headache and Behavioral Changes. *N Engl J Med* 359: 842-853.
6. Peery HE, Day GS, Dunn S, Fritzier MJ, Prüss H, et al. (2012) Anti-NMDA receptor encephalitis. The disorder, the diagnosis and the immunobiology. *Autoimmun Rev* 11: 863-872.
7. Kawano H, Hamaguchi E, Kawahito S, Tsutsumi YM, Tanaka K, et al. (2011) Anaesthesia for a patient with paraneoplastic limbic encephalitis with ovarian teratoma: relationship to anti-N-methyl-D-aspartate receptor antibodies. *Anaesthesia* 66: 515-518.

8. Orser BA, Bertlik M, Wang LY, MacDonald JF (1995) Inhibition by propofol (2,6 di-isopropylphenol) of the N-methyl-D-aspartate subtype of glutamate receptor in cultured hippocampal neurones. *Br J Pharmacol* 116: 1761-1768.
9. Lapébie F-X, Kennel C, Magy L (2014) Potential side effect of propofol and sevoflurane for anesthesia of anti-NMDA-R encephalitis. *BMC Anesthesiol* 14: 5.
10. Dunn, Peter F (2007) *Clinical Anesthesia Procedures of the Massachusetts General Hospital*, 7th Edition, Lippincott Williams and Wilkins.
11. Pryzbylkowski PG, Dunkman WJ, Liu RY, Chen L (2011) Case report: Anti-N-Methyl-D-Aspartate Receptor Encephalitis and its Anesthetic Implications. *Anesth Analg* 113: 1188-1191.
12. Hollman MW, Liu H-T, Hoenemann CW, Liu W-H, Durieux ME (2001) Modulation of NMDA receptor function by ketamine and magnesium. Part II: interaction with volatile anesthetics. *Anesth Analg* 92: 1182-1191.
13. McCartney CJL, Sinha A, Katz JA (2004) A qualitative systematic review of the role of N-methyl-D-aspartate receptor antagonists in preventive analgesia. *Anesth Analg* 98: 1385-1400.